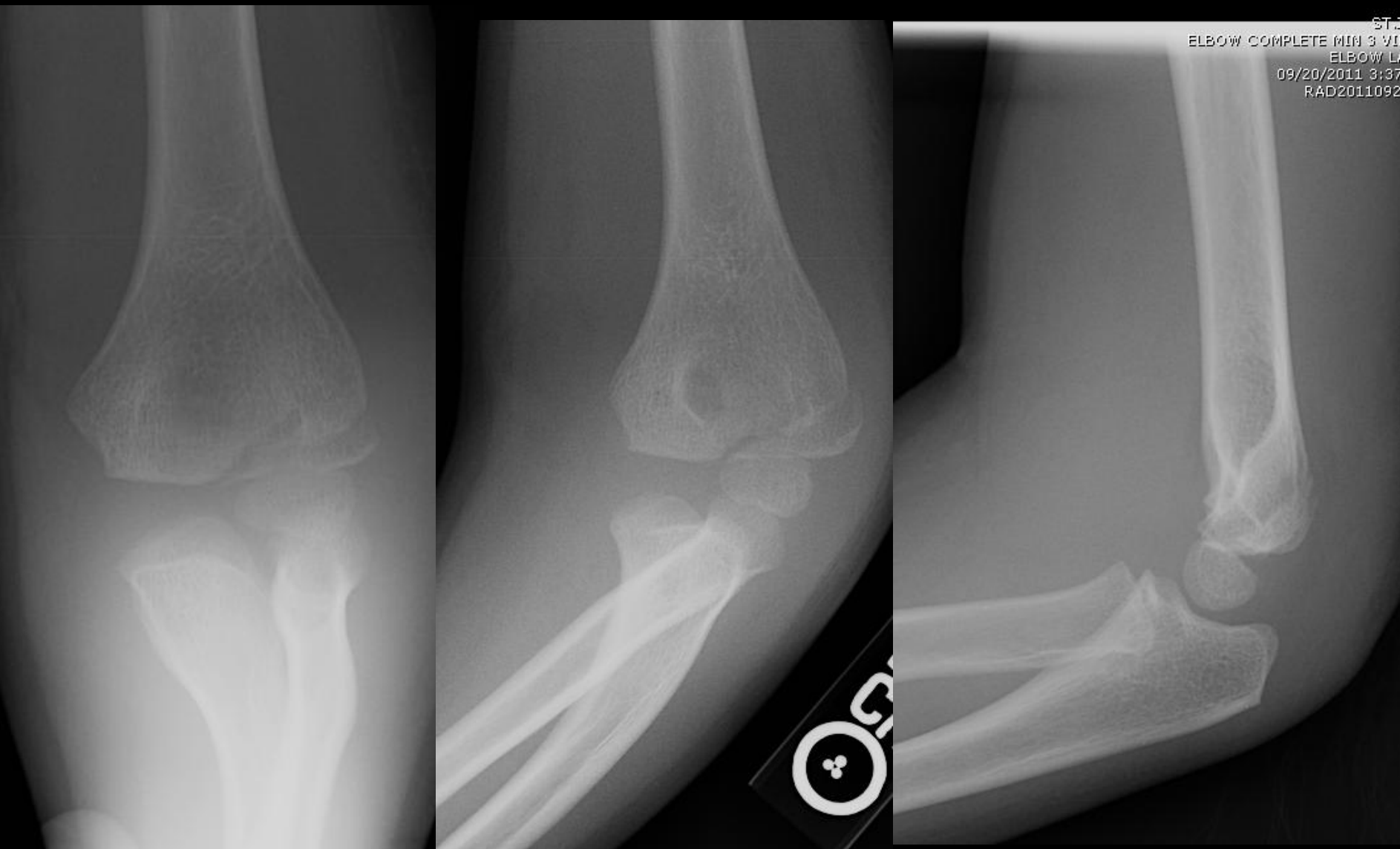
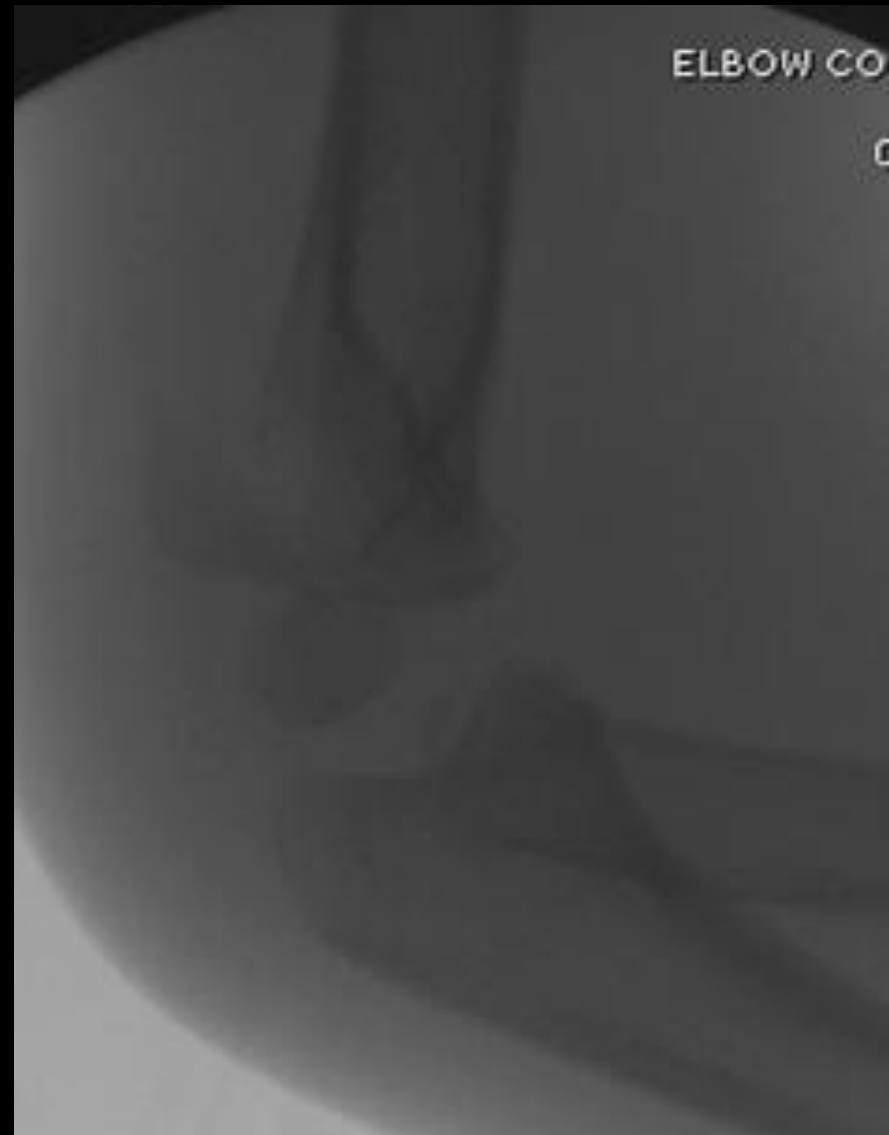
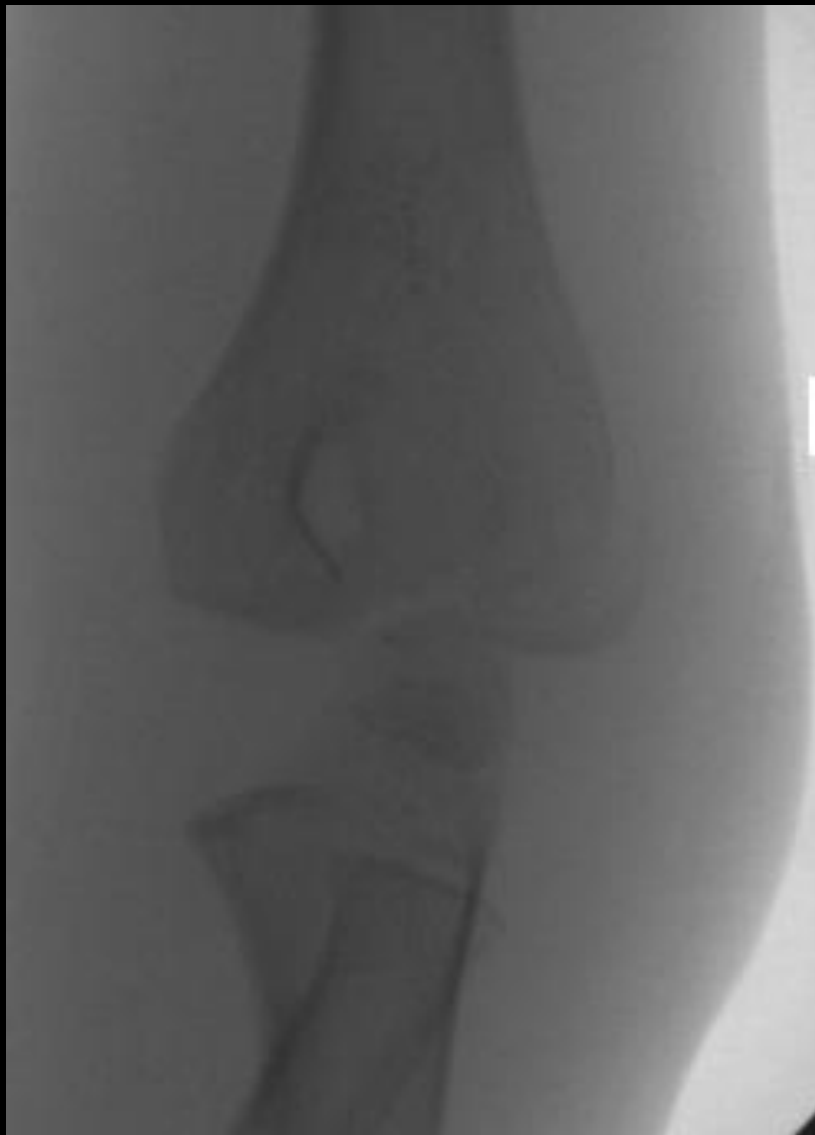
5 y ♂ - Lateral Condyle Fracture Humerus



Intra-Op Fluoroscopic Images



Open Treatment with Pinning

