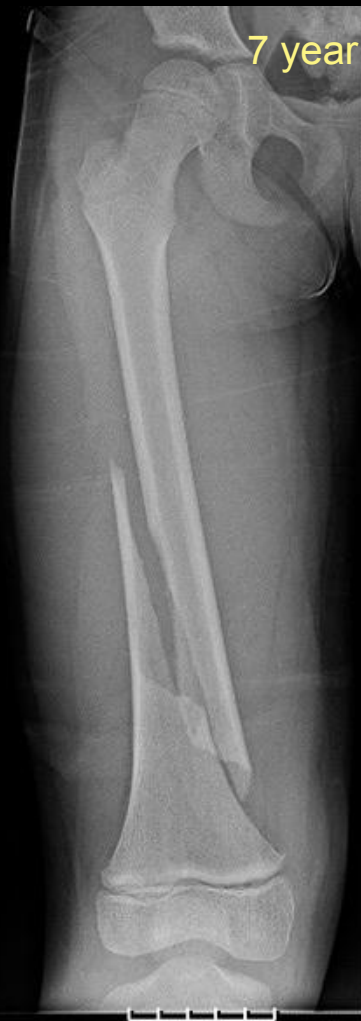
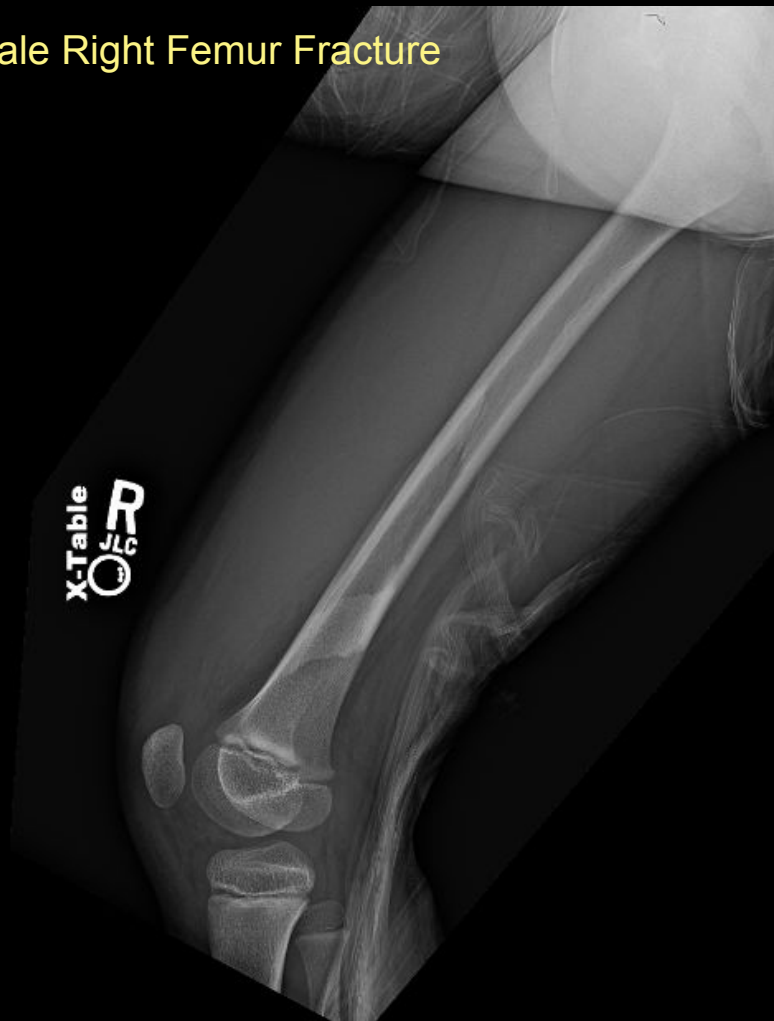
7 year old Female Right Femur Fracture

R  
JLC



X-Table  
JLC  
R



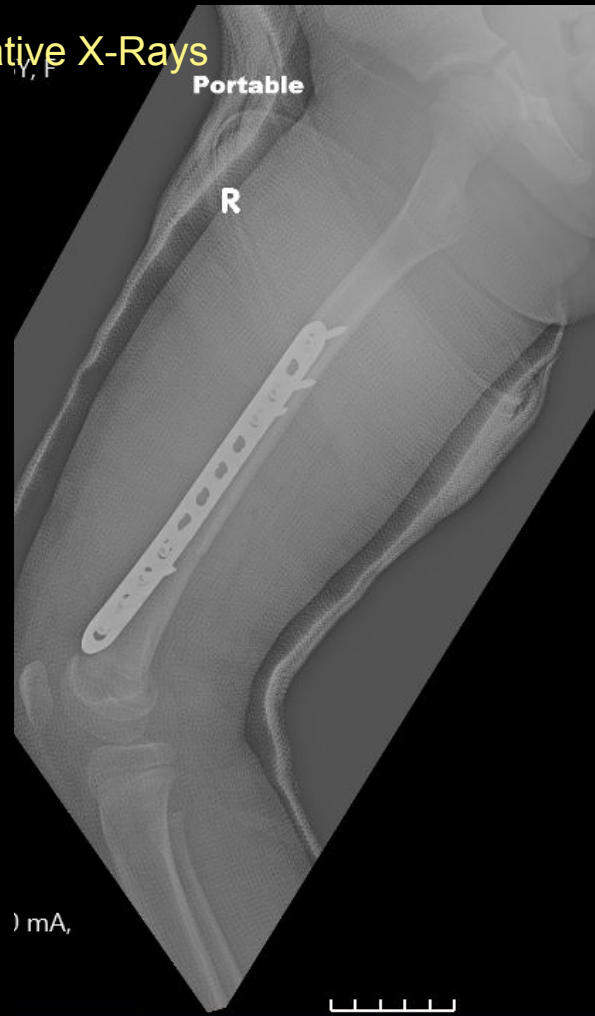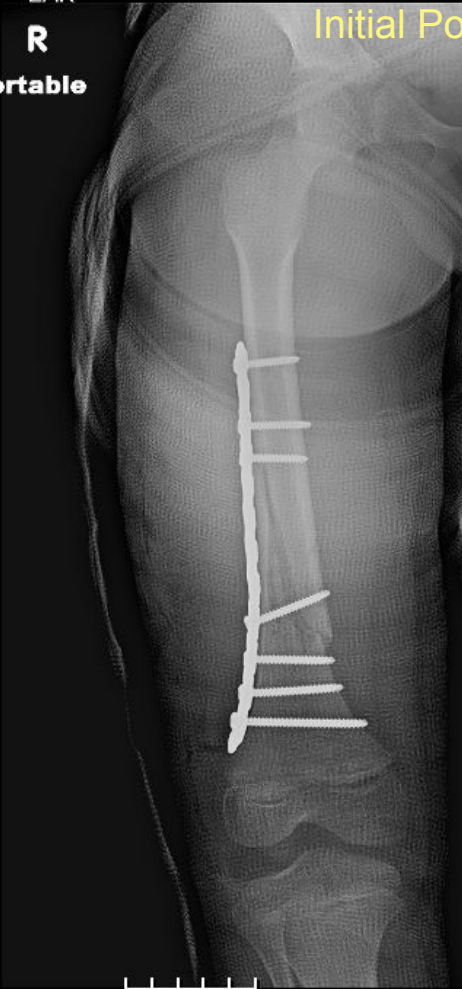
7/18/2017

EAK

R

Portable

# Initial Post Operative X-Rays



Portable

R

) mA,



7/18/2017

13 years old with Plate Migration and Valgus Limb Deformity

R  
LV

C

R  
LV

R  
LV

3/18/2023

