

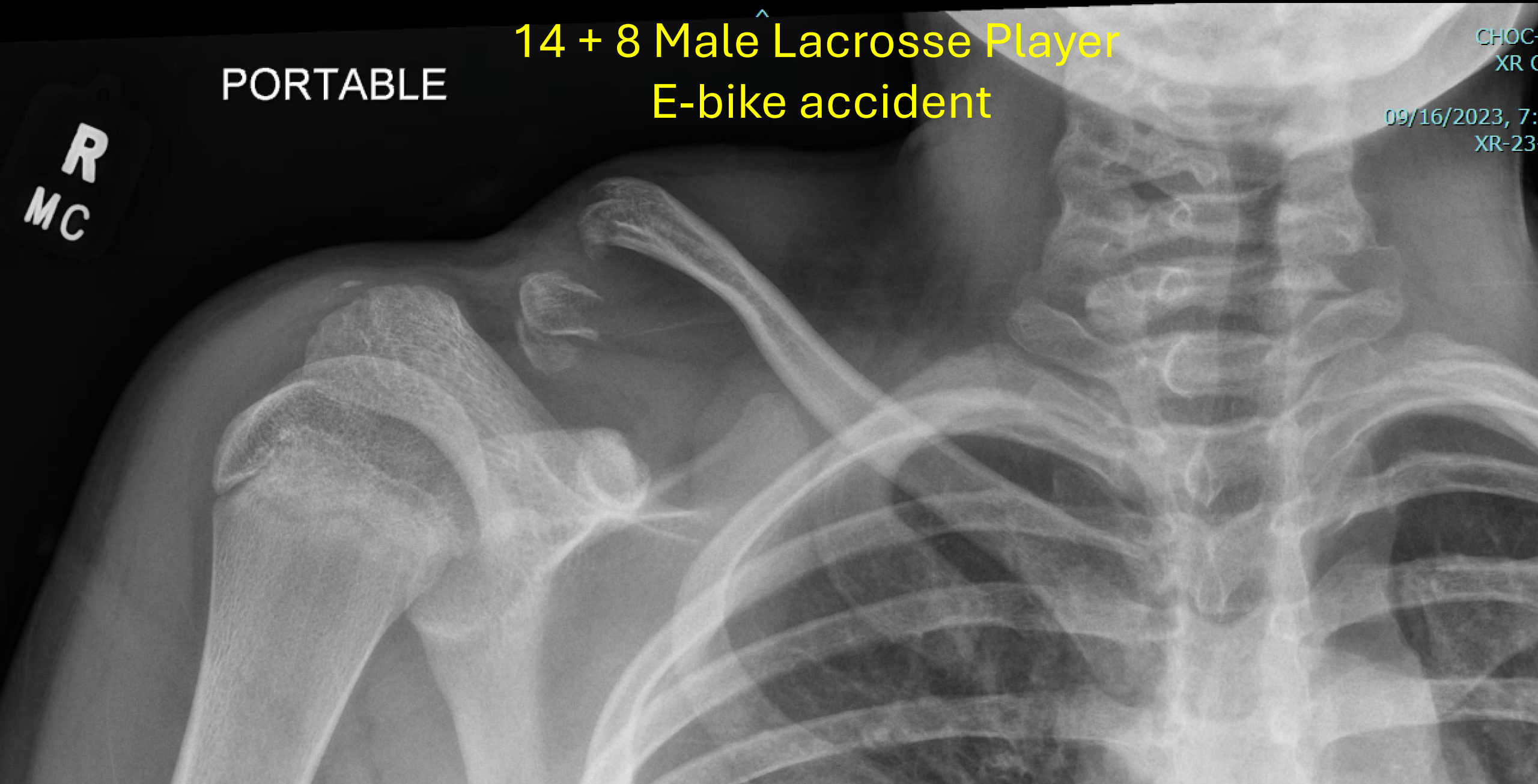
14 + 8 Male Lacrosse Player
E-bike accident

PORTABLE

R
MC

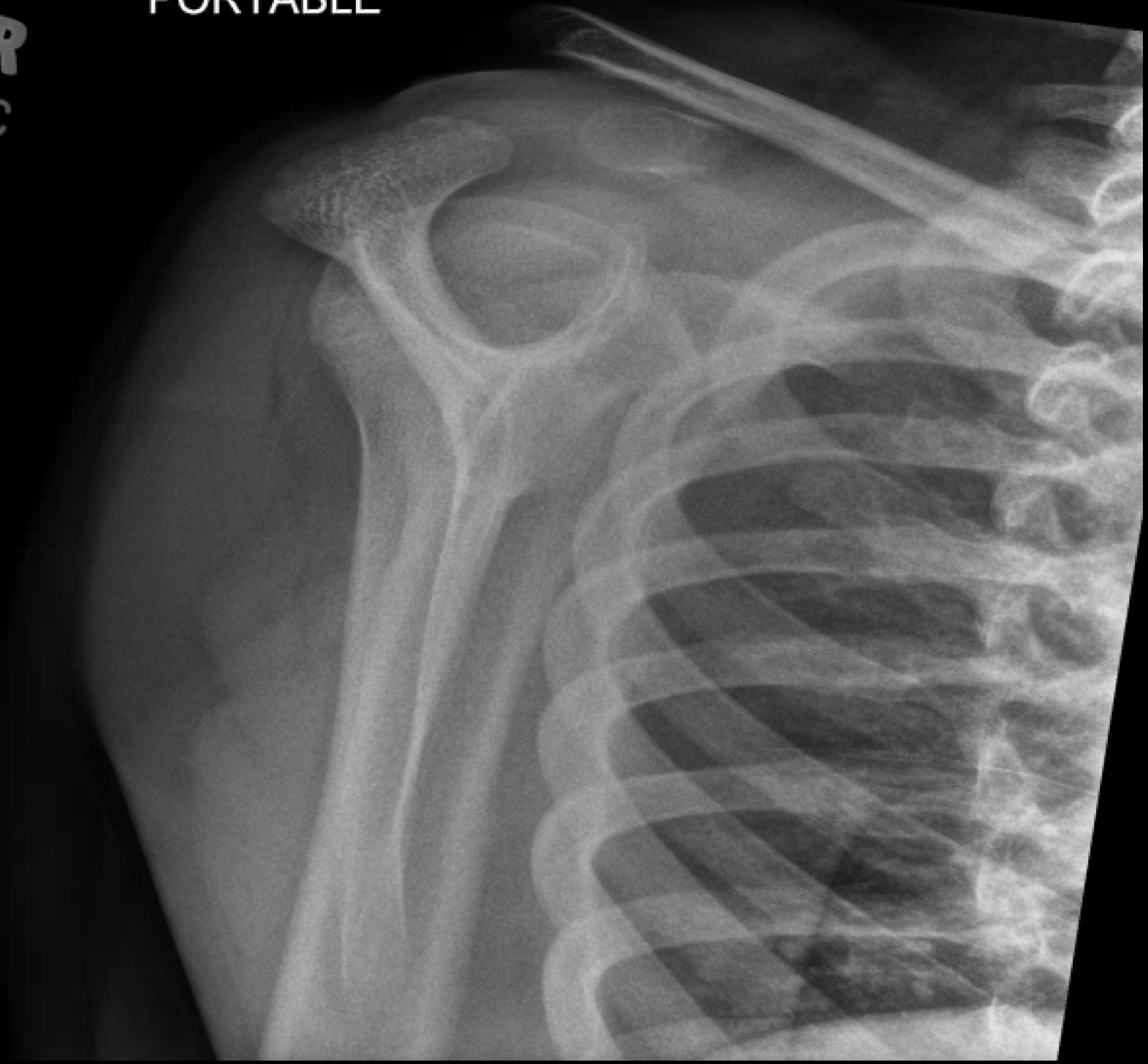CHOC-
XR C

09/16/2023, 7:
XR-23



PORTABLE

R
MC



PORTABLE

14 + 8 boy E-bike accident

CHOC-
XR C

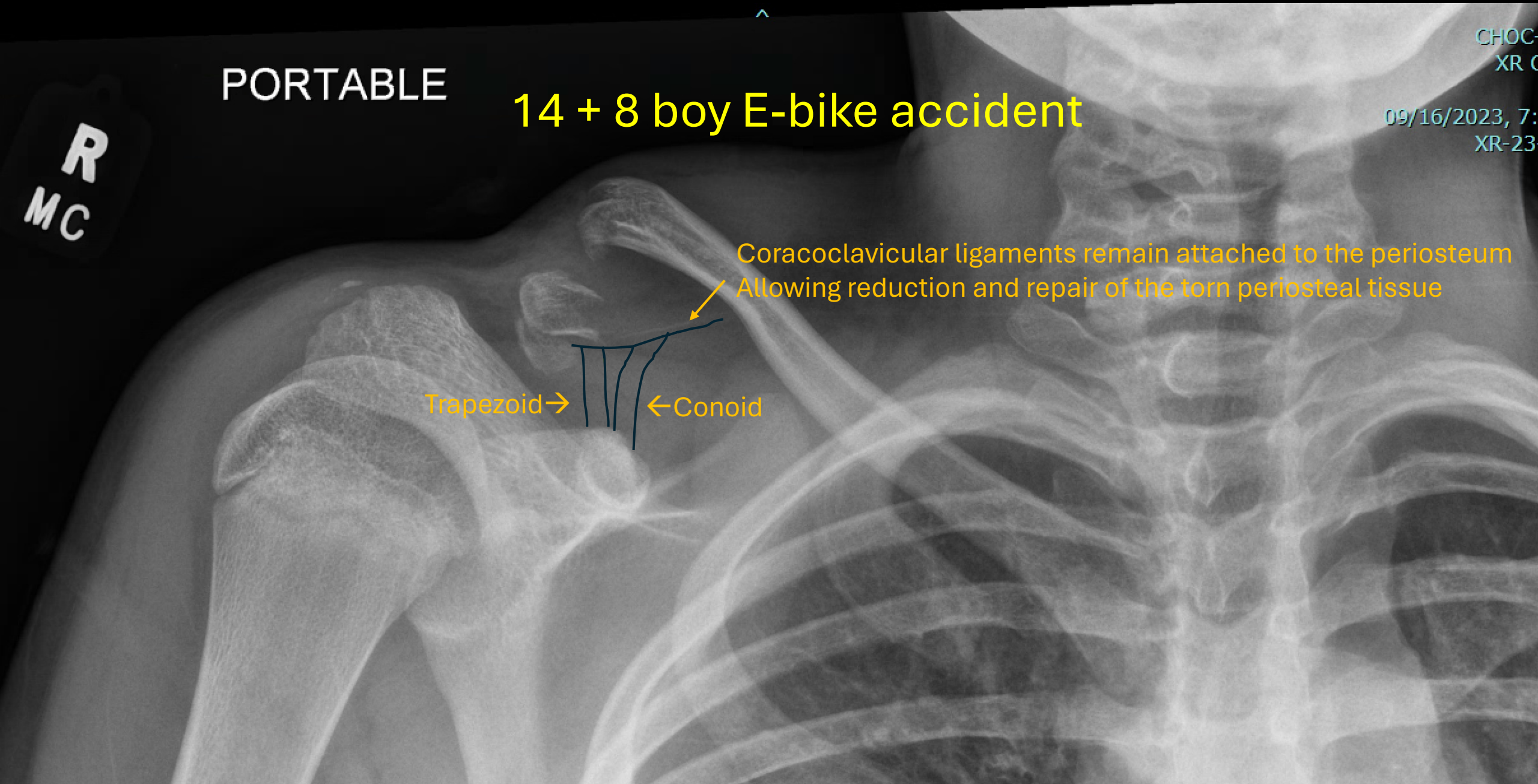
09/16/2023, 7:
XR-23

R
MC

Coracoclavicular ligaments remain attached to the periosteum
Allowing reduction and repair of the torn periosteal tissue

Trapezoid →

← Conoid



Intraoperative Displacement

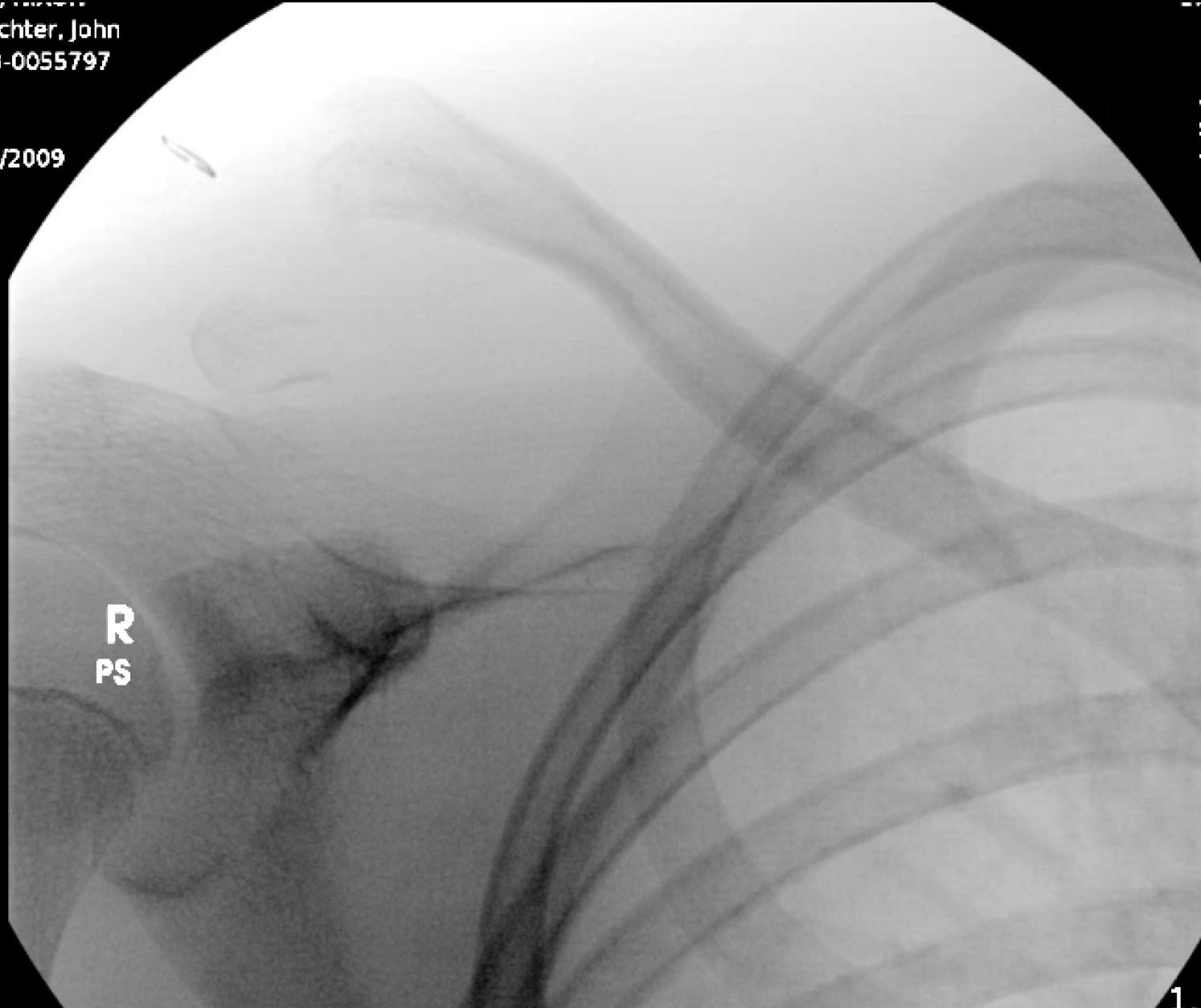Schlechter, John
XR-23-0055797

01/07/2009
M

32⚙️
320

R
PS

1.0X⊕



Intraoperative Position Following Periosteal Repair

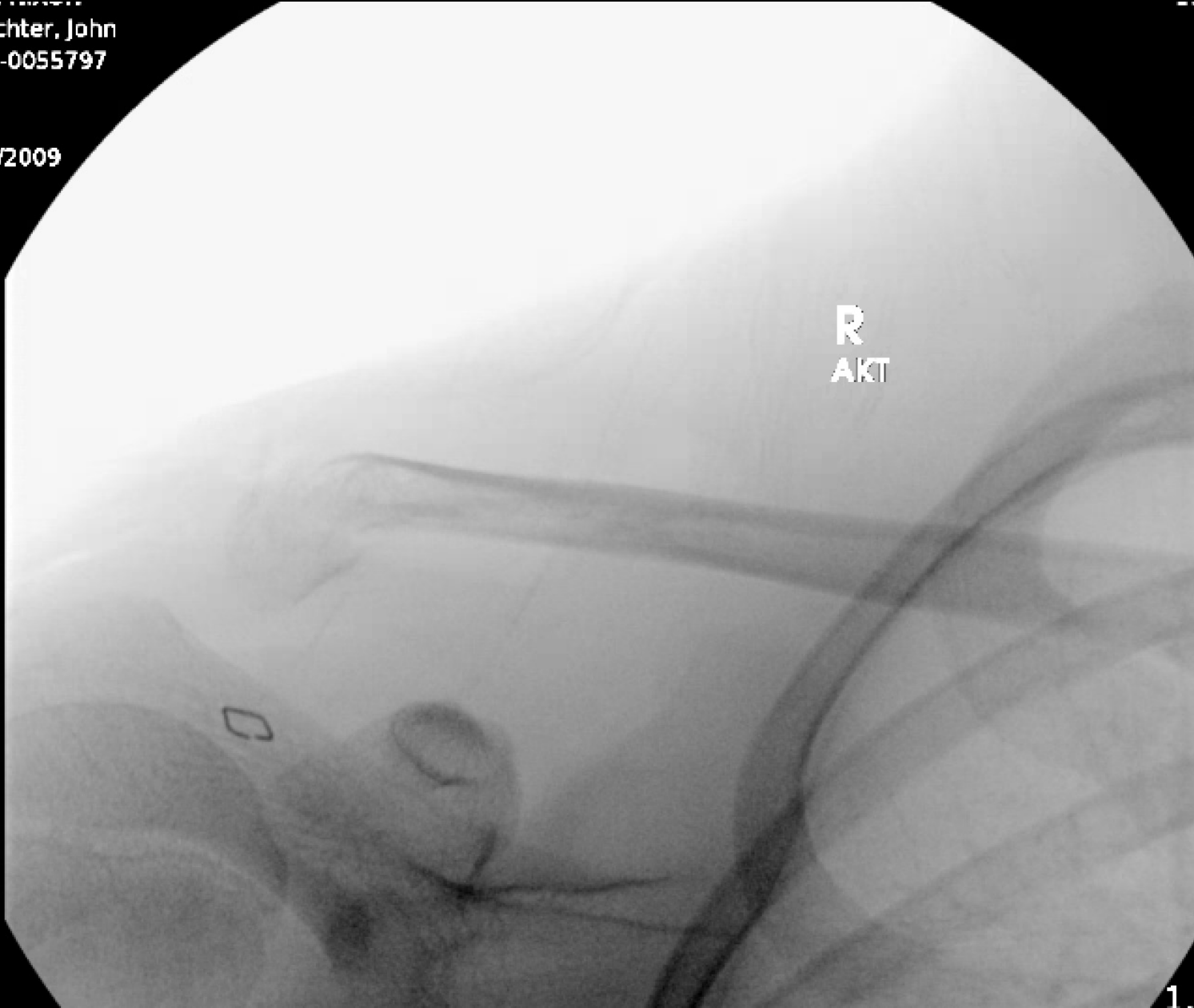
Schlechter, John
XR-23-0055797

01/07/2009
M

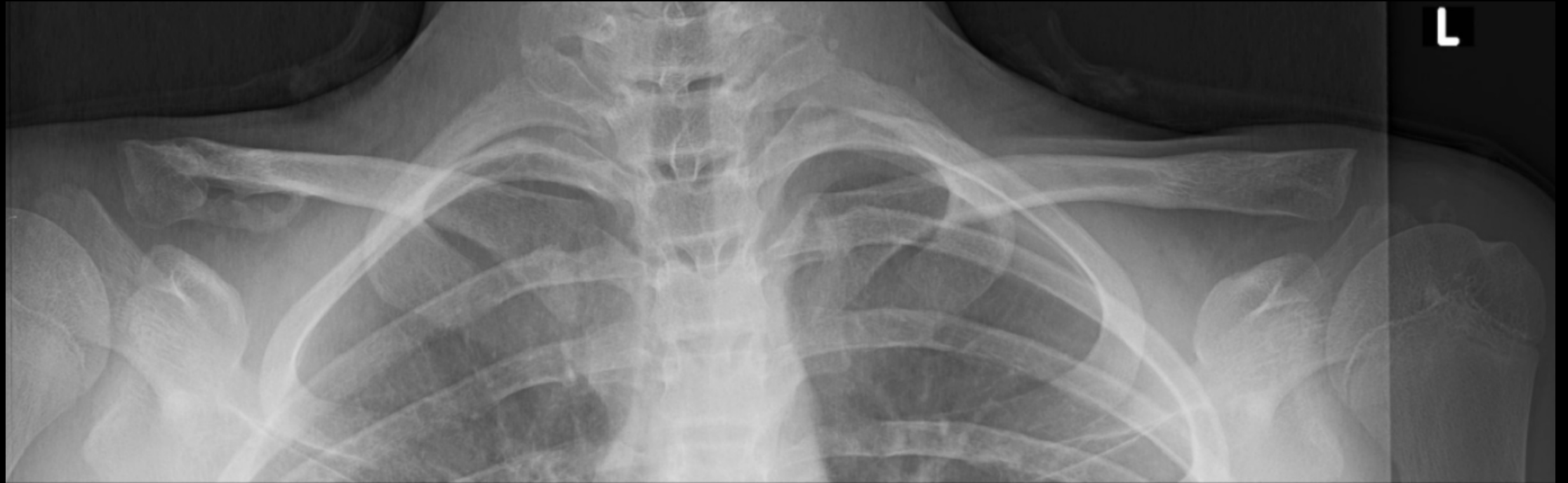
29⊗
26⊙

R
AKT

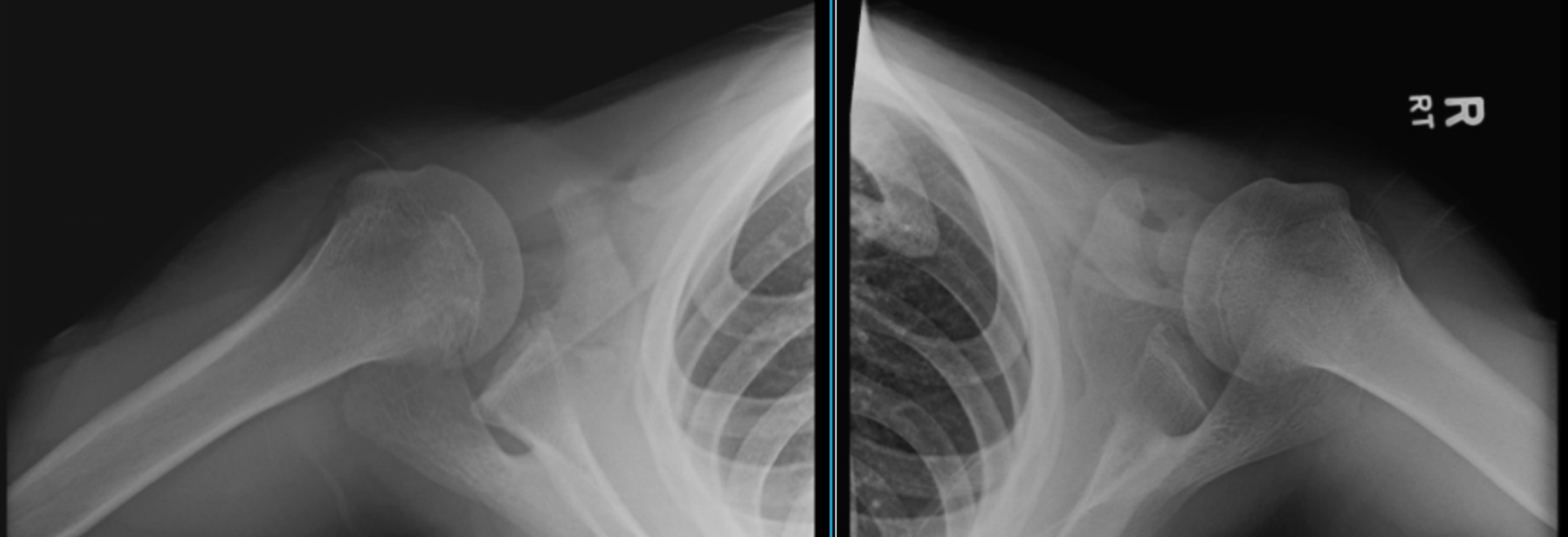
1.0X⊕



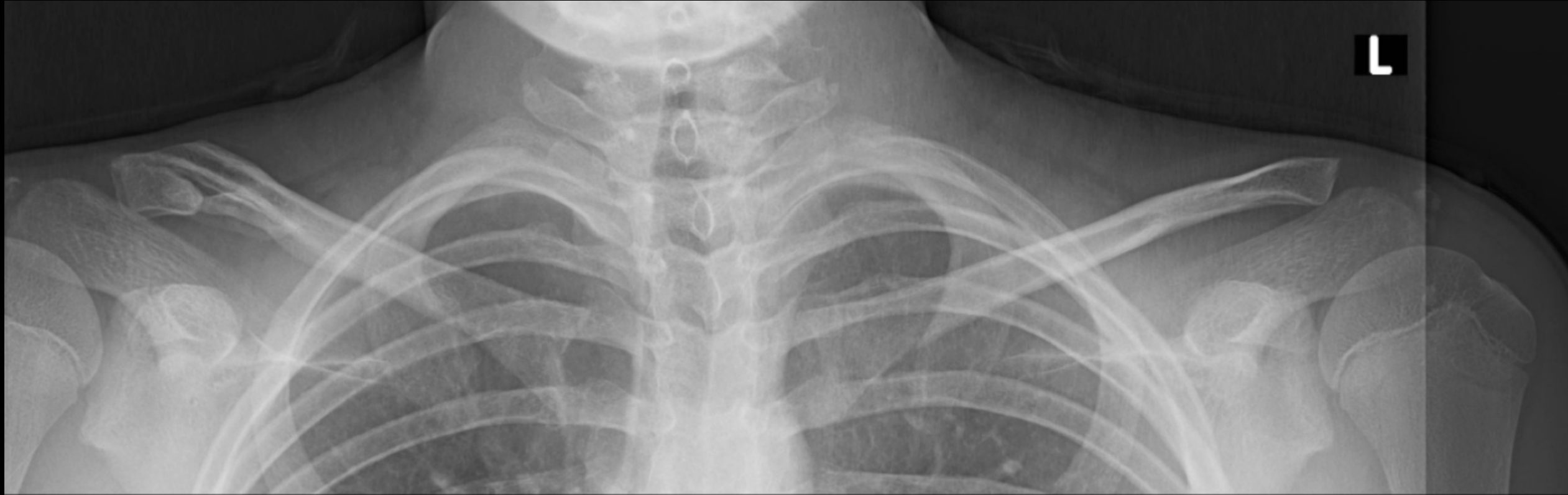
4 month Post-operative X-ray



4 month Post-operative X-ray



4 month Post-operative X-ray



Returned to Lacrosse without restrictions