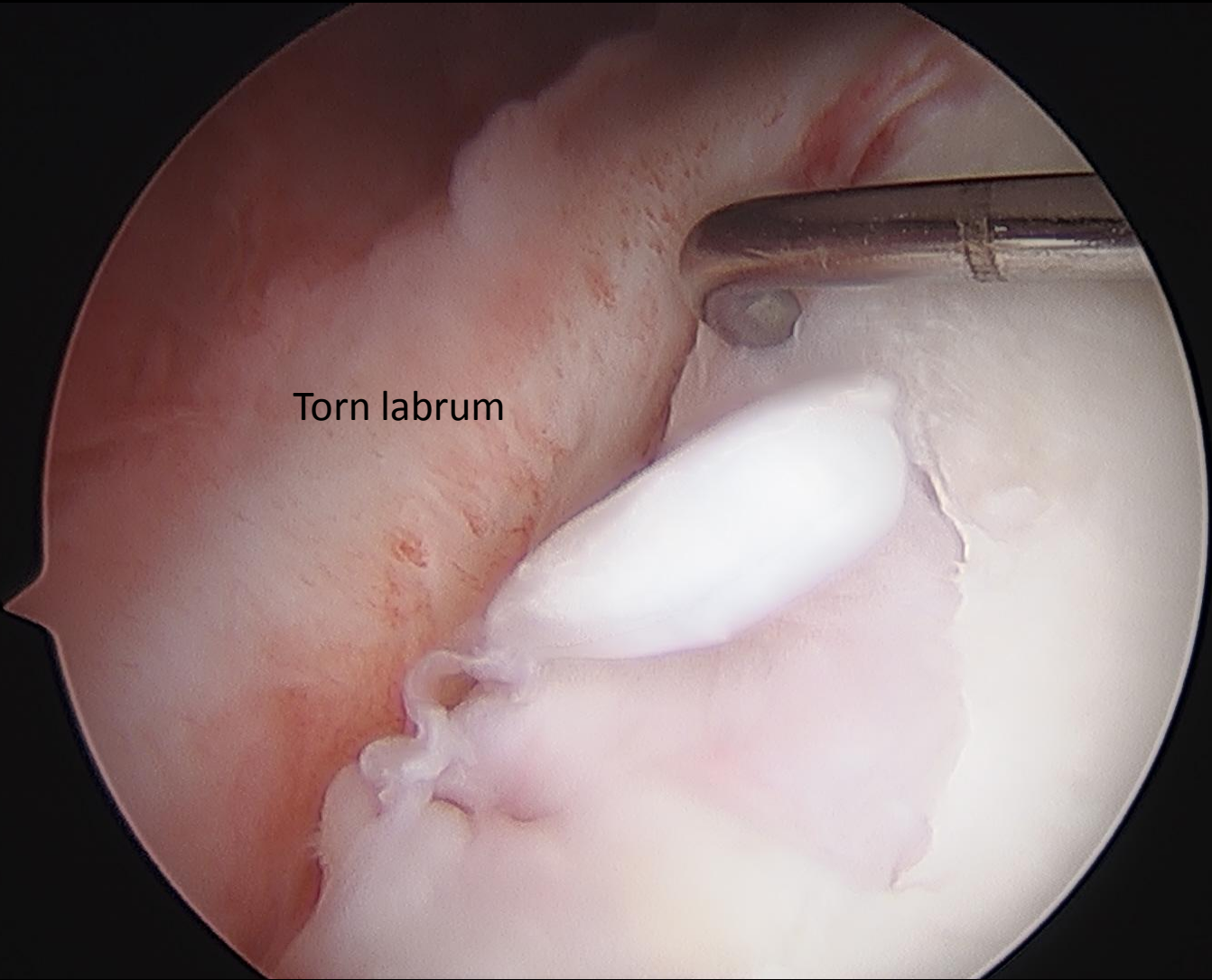
An arthroscopic view of a shoulder joint. A metal surgical instrument is visible on the left side, interacting with the labrum. The labrum is a ring of fibrocartilage that sits on the rim of the acetabulum. The image shows a normal, healthy labrum with a smooth, white surface. The acetabulum is visible as a smooth, white, curved surface. The text "Normal labrum" is overlaid on the image, and "socket" is also overlaid. The background is dark, likely the surrounding soft tissue.


Normal labrum

socket

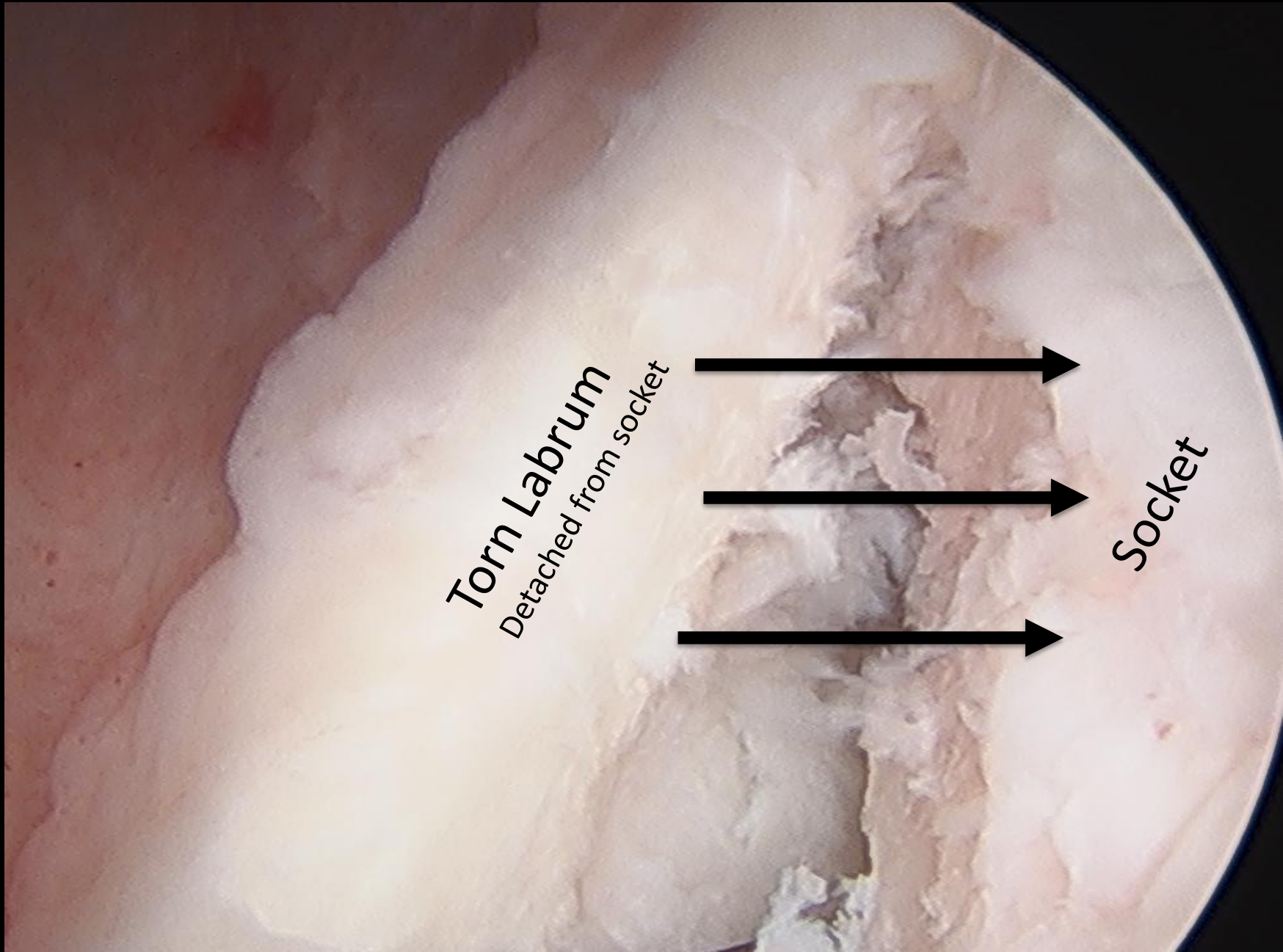


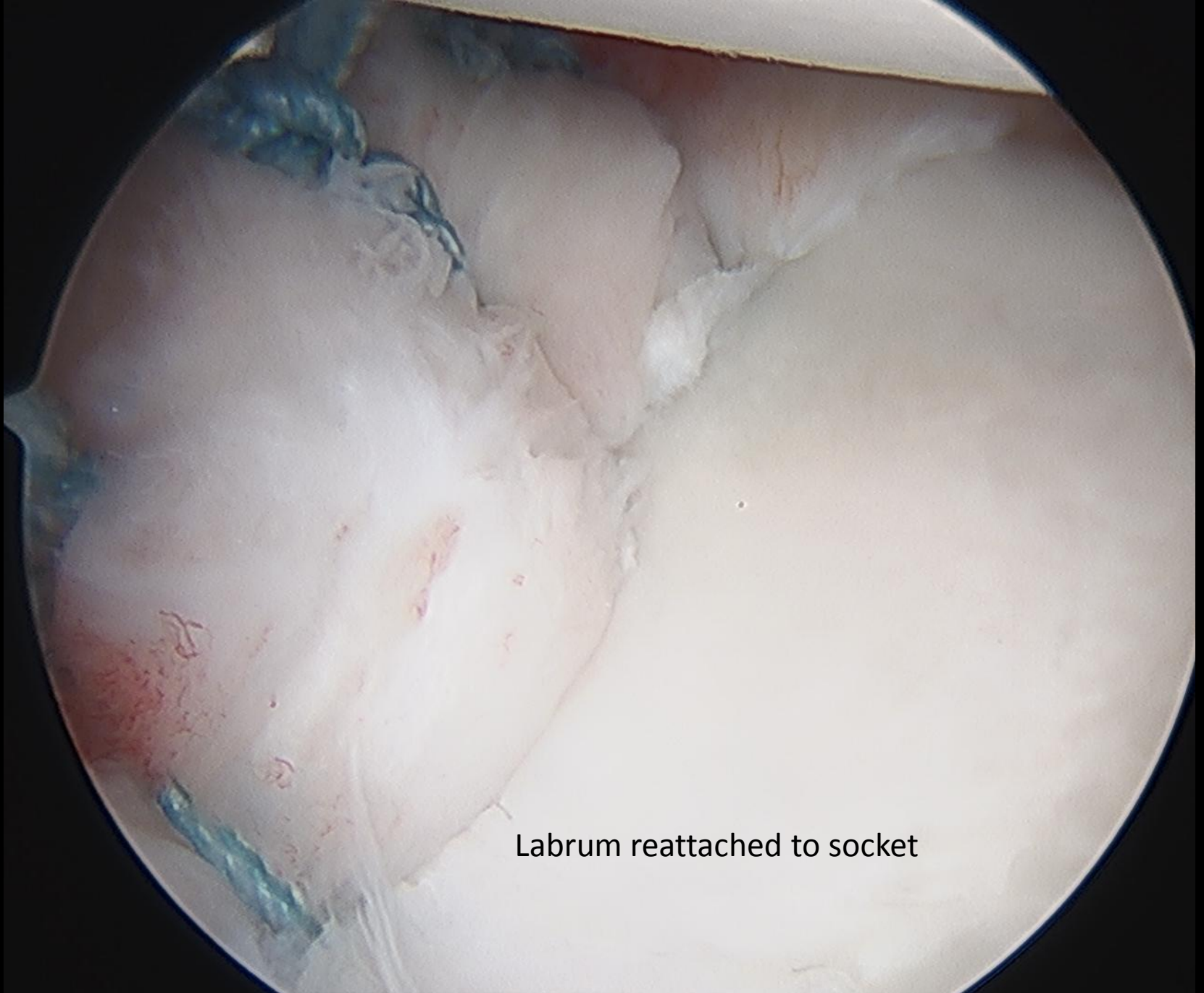
Torn labrum

Torn Labrum
Detached from socket



Socket





Labrum reattached to socket

Ball

Repaired labrum

Socket

