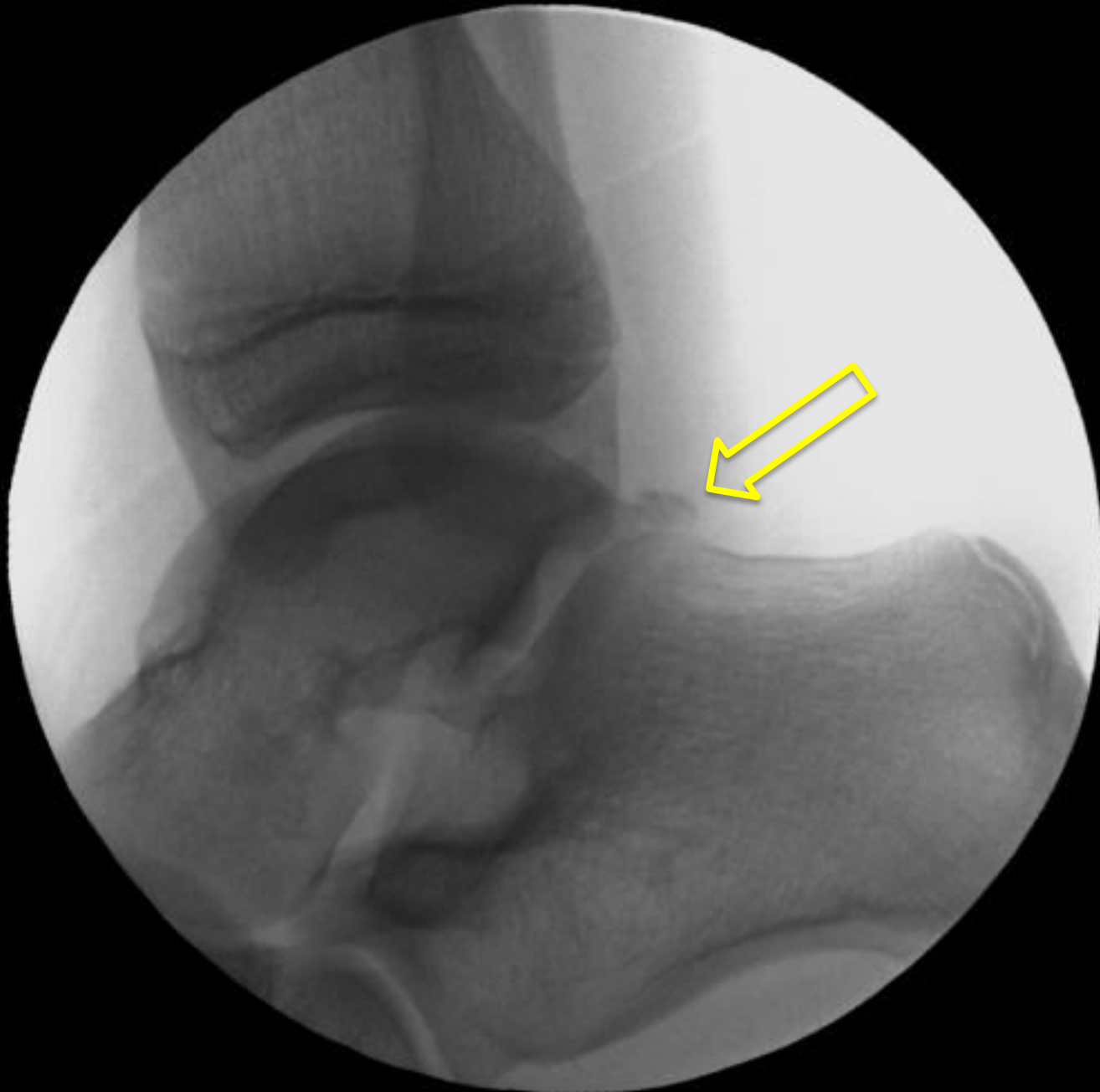

Arthroscopic Excision of Os Trigonum

John A. Schlechter, DO, FAOAO

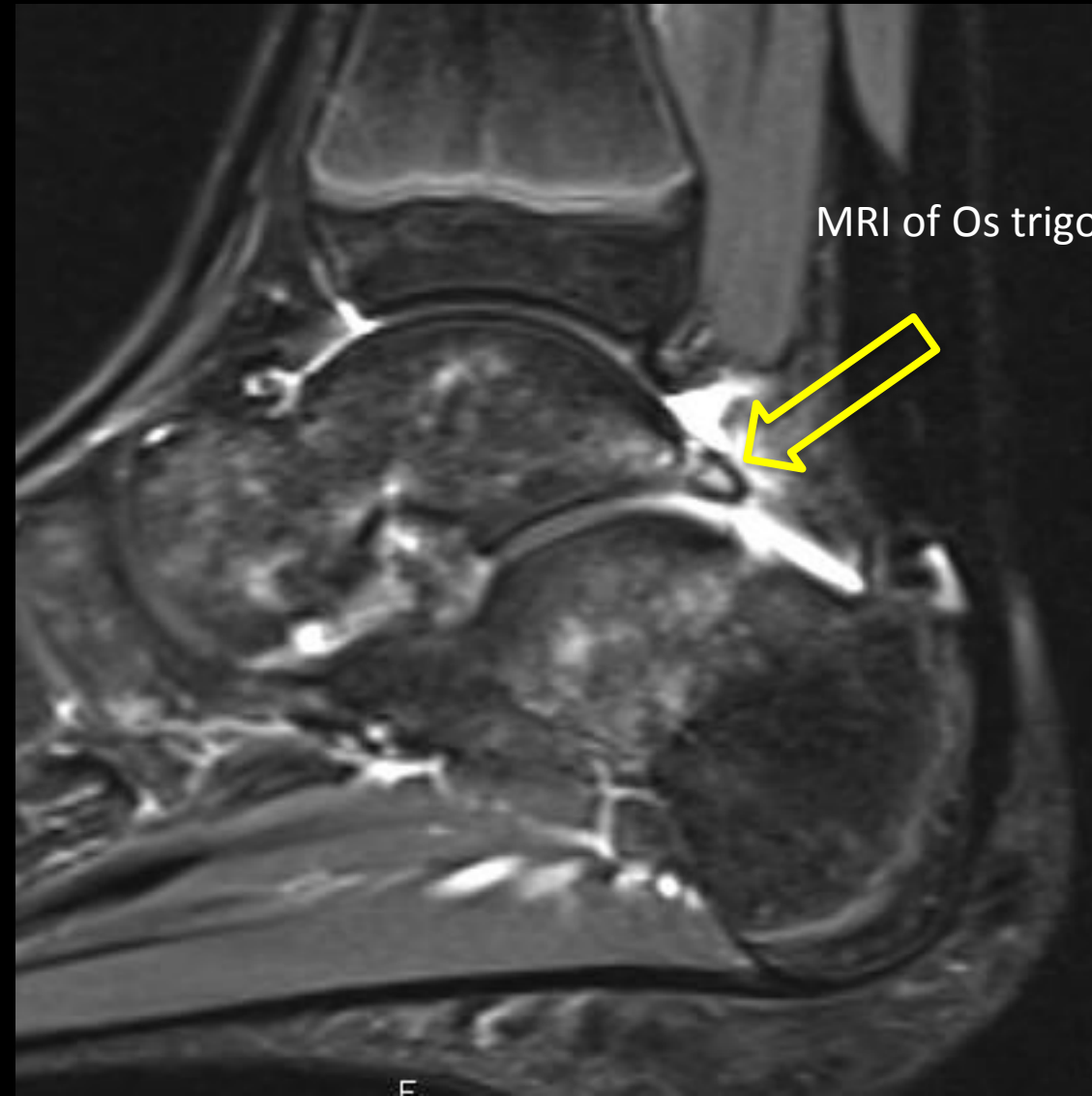14 yo Ballerina

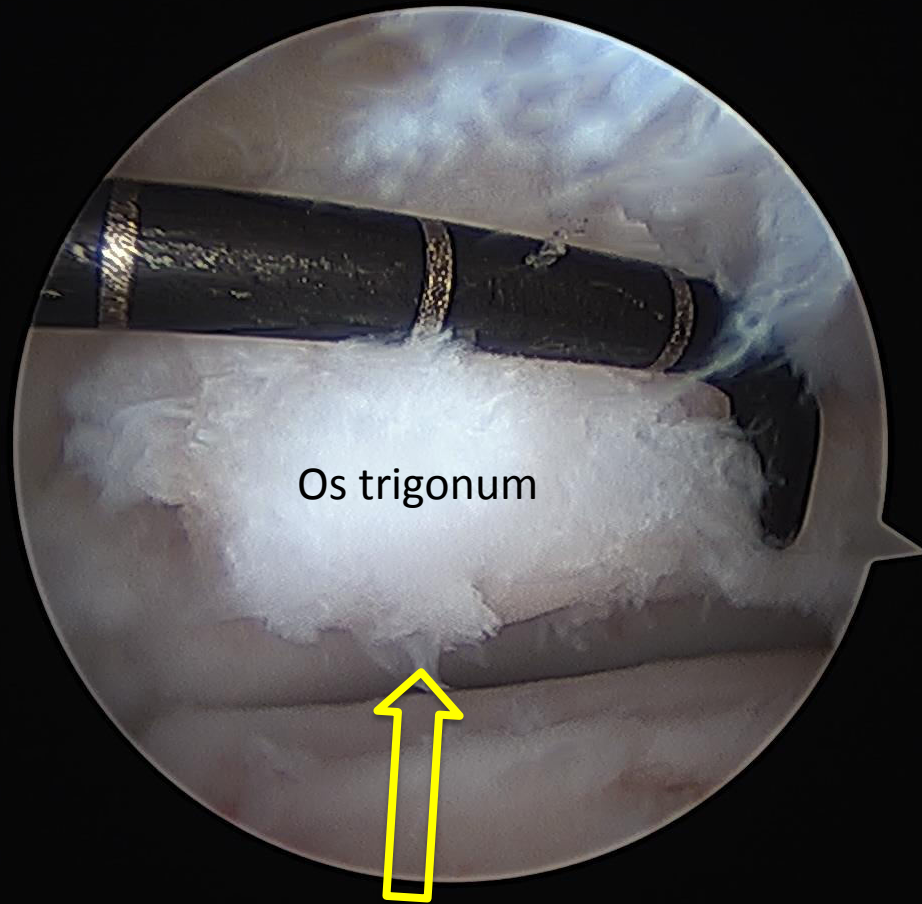
- 6 month history of pain in the back of her ankle
- Pain is worse when en pointe



Intra-operative X-Ray of Os trigonum

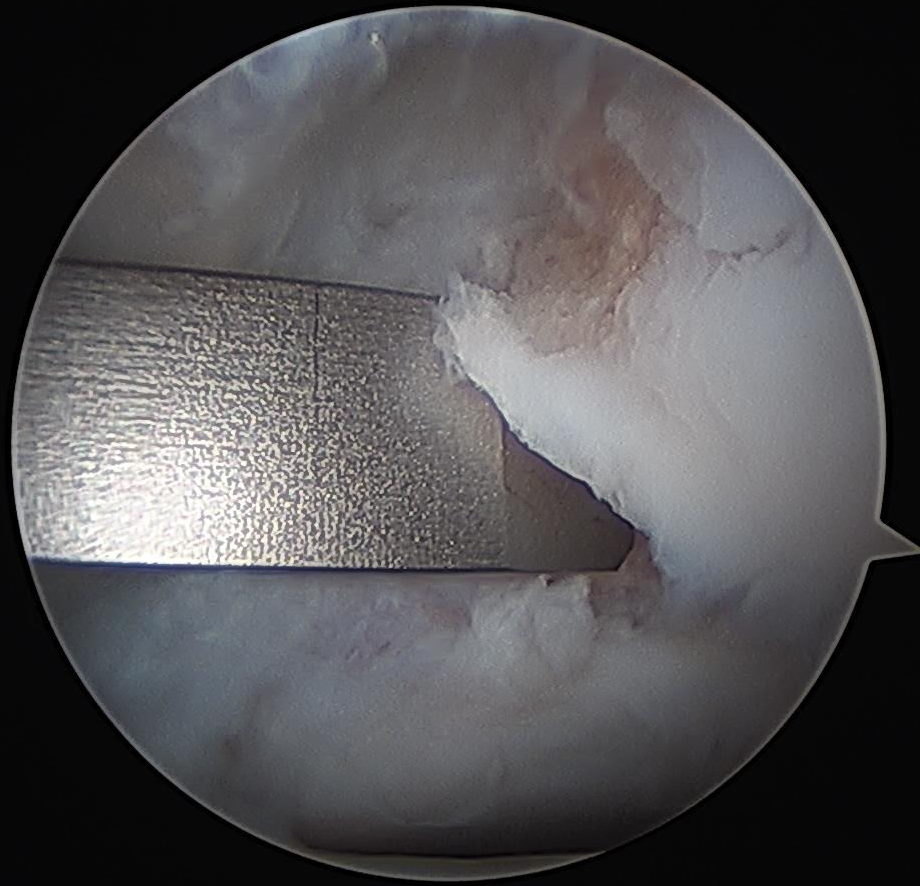
MRI of Os trigonum with surrounding swelling (white)



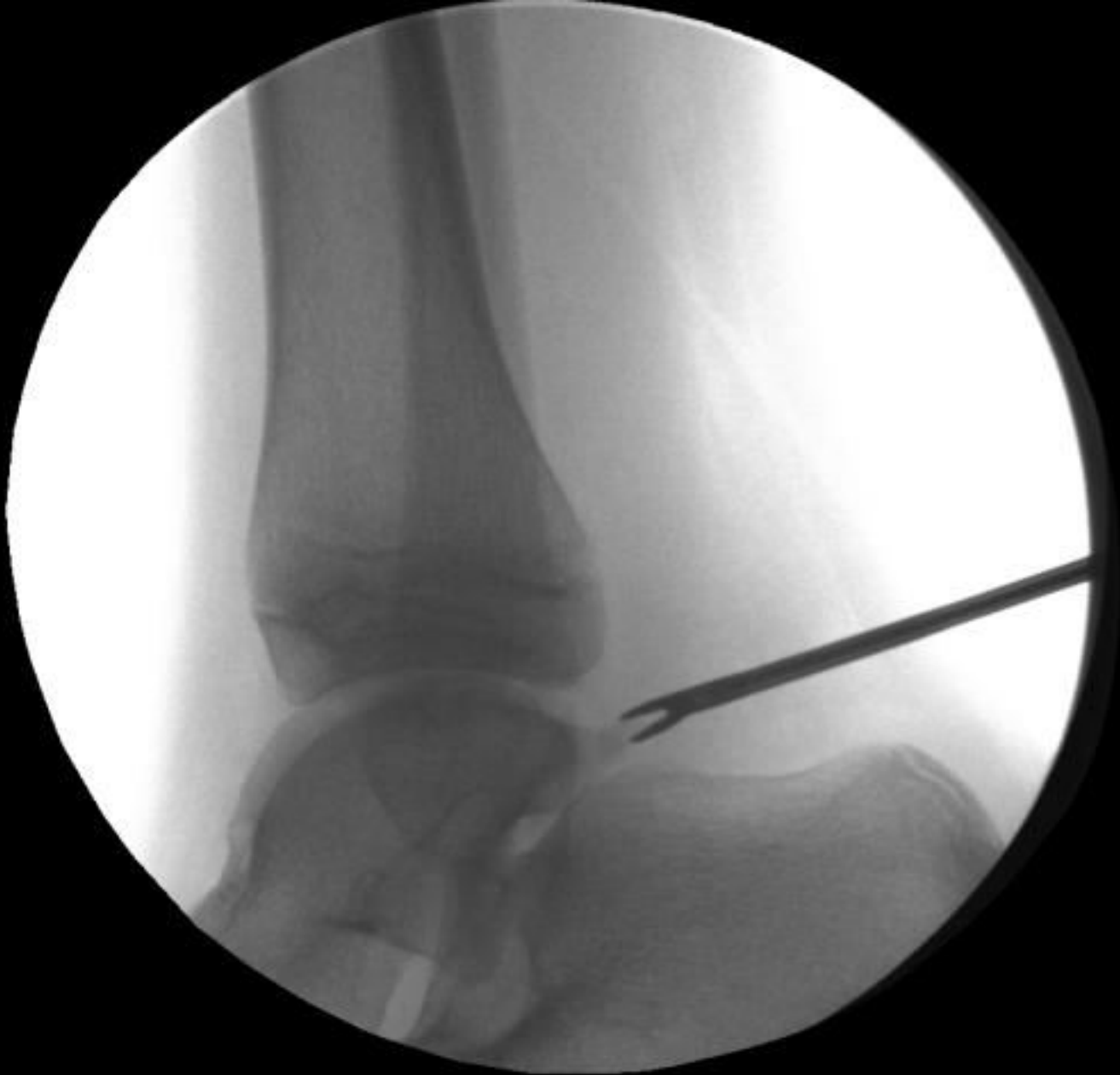

Os trigonum

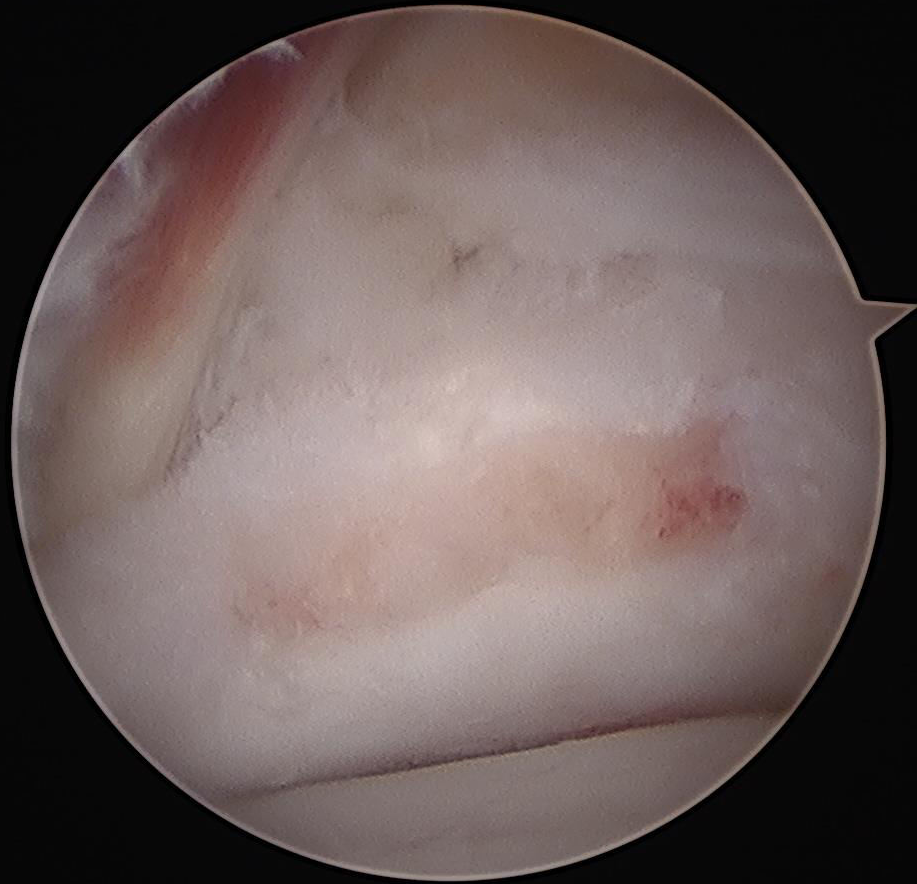Arthroscopic View of Os trigonum with measuring probe

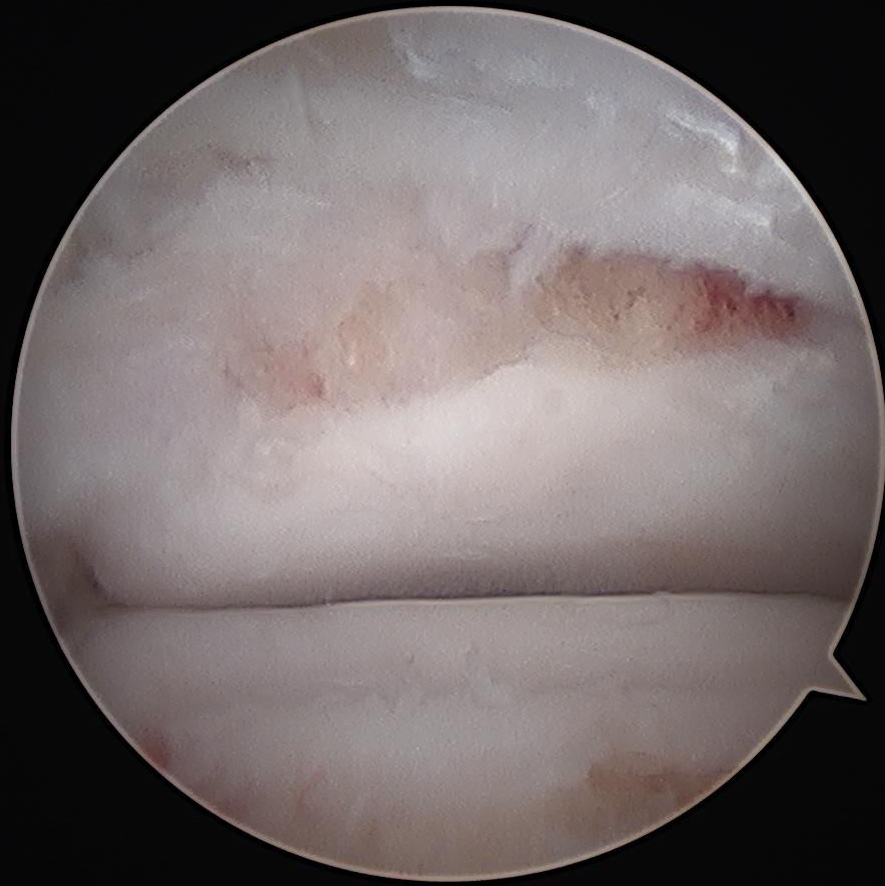

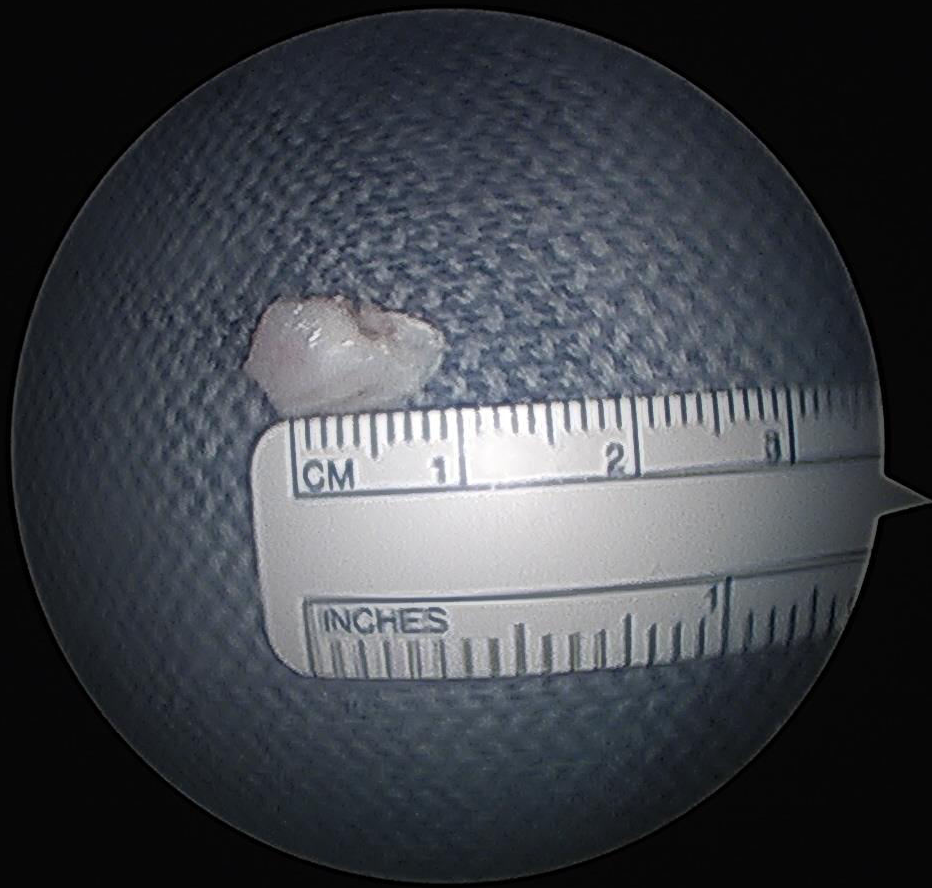Elevation and preparation for arthroscopic removal of Os trigonum

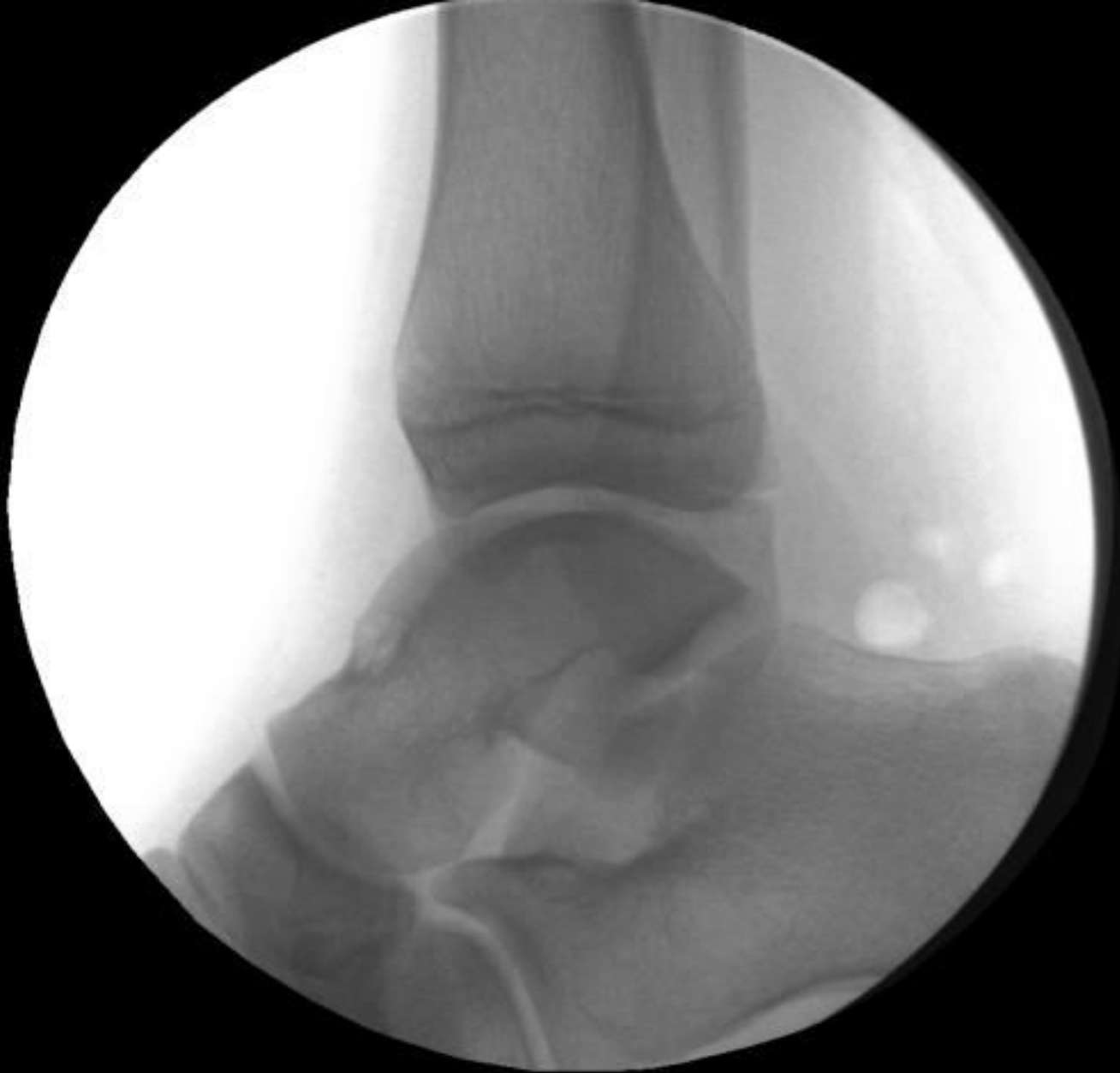

Removal with Arthroscopic Grasper









Intra-operative X-Ray following resection of Os trigonum