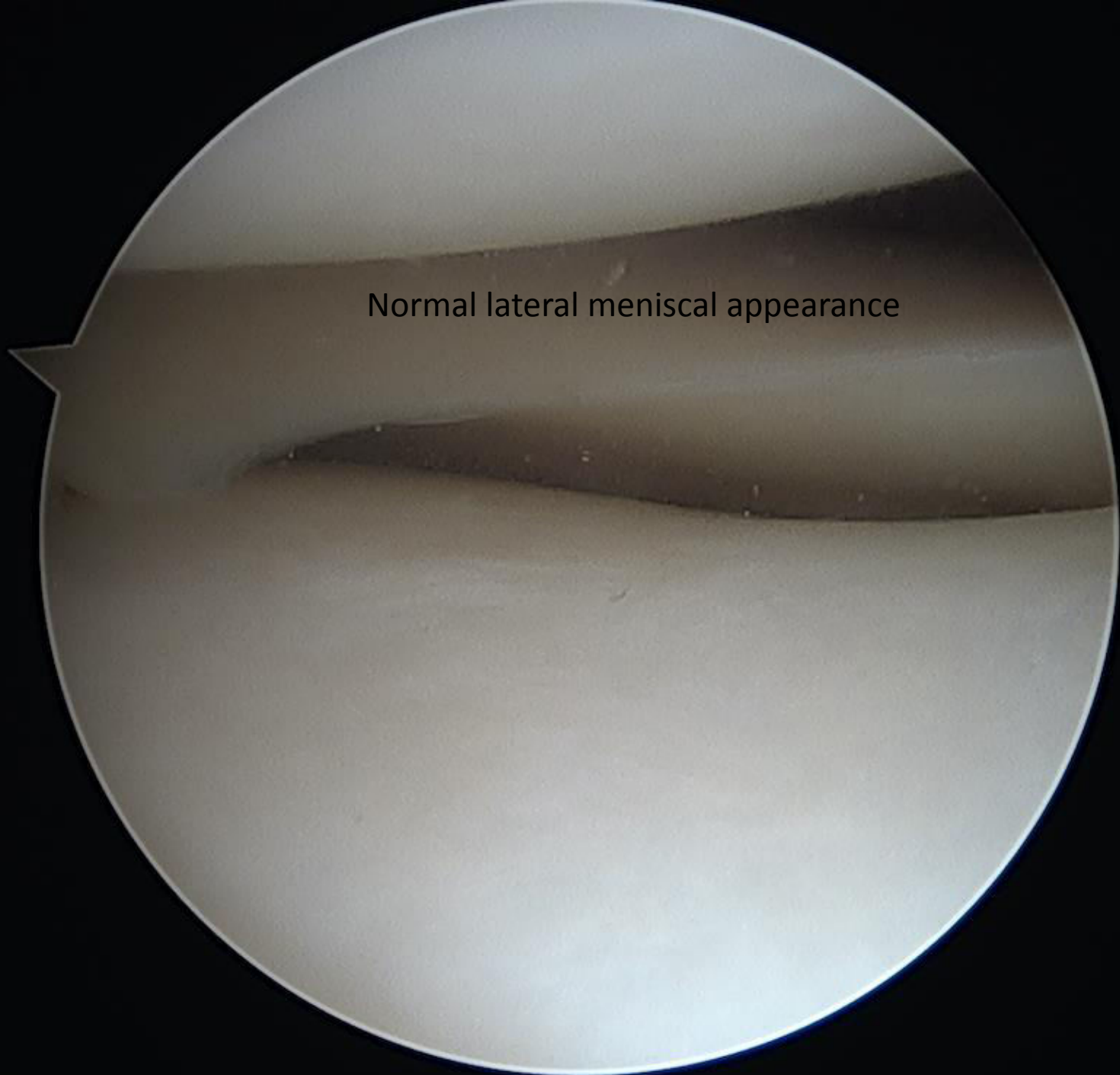


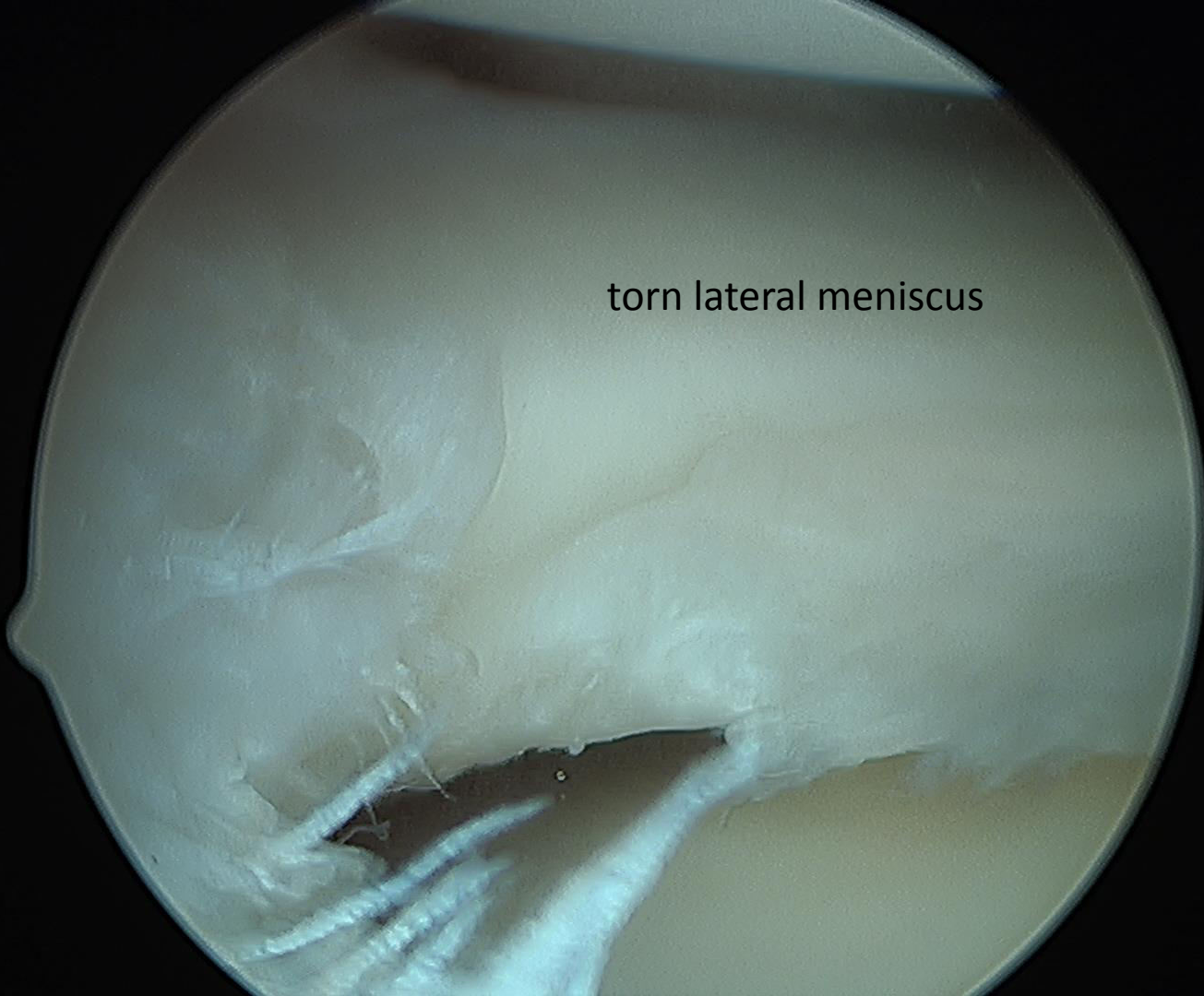
# Arthroscopic Partial Lateral Meniscectomy

John A. Schlechter, DO, FAOAO




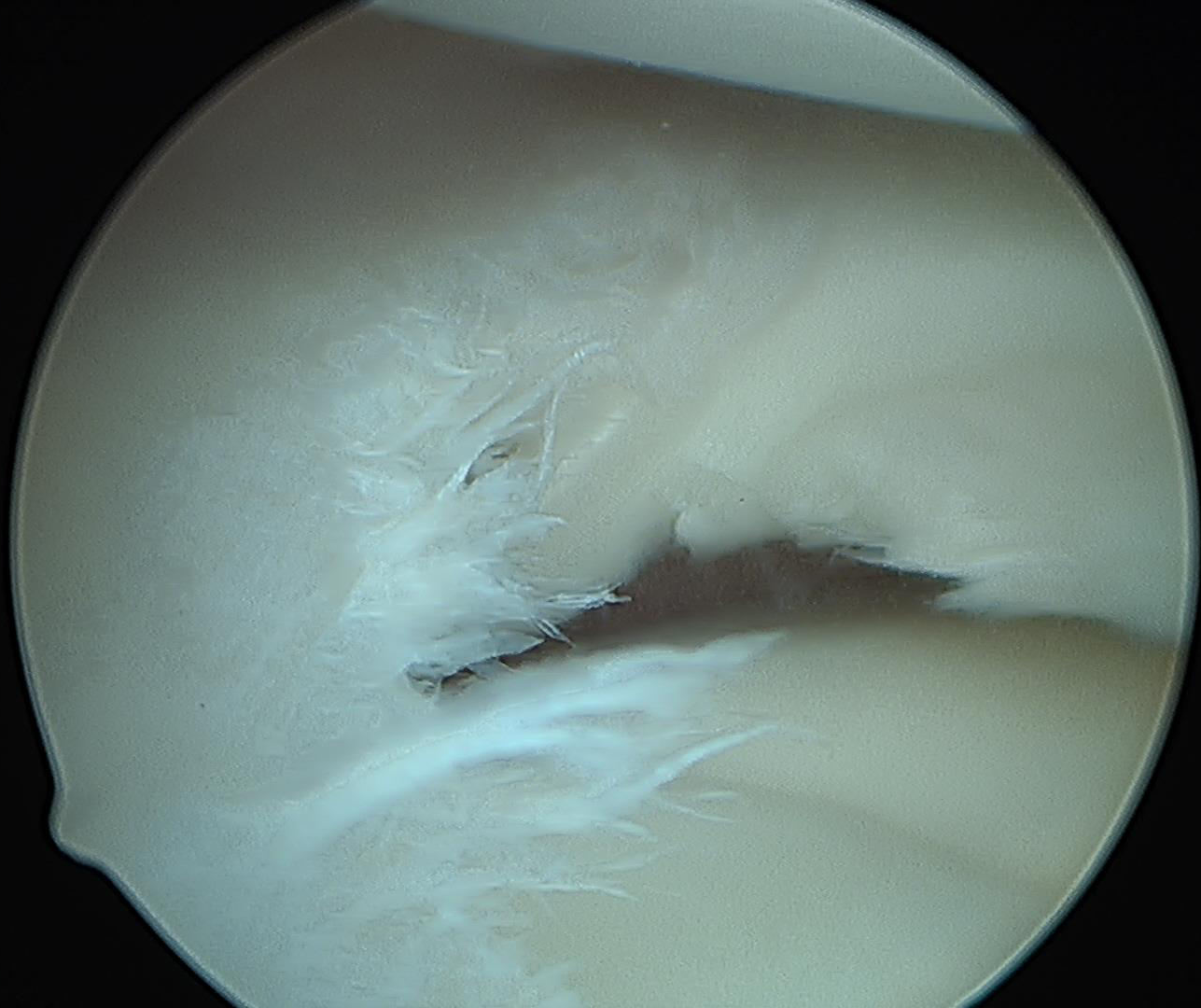
Normal lateral meniscal appearance

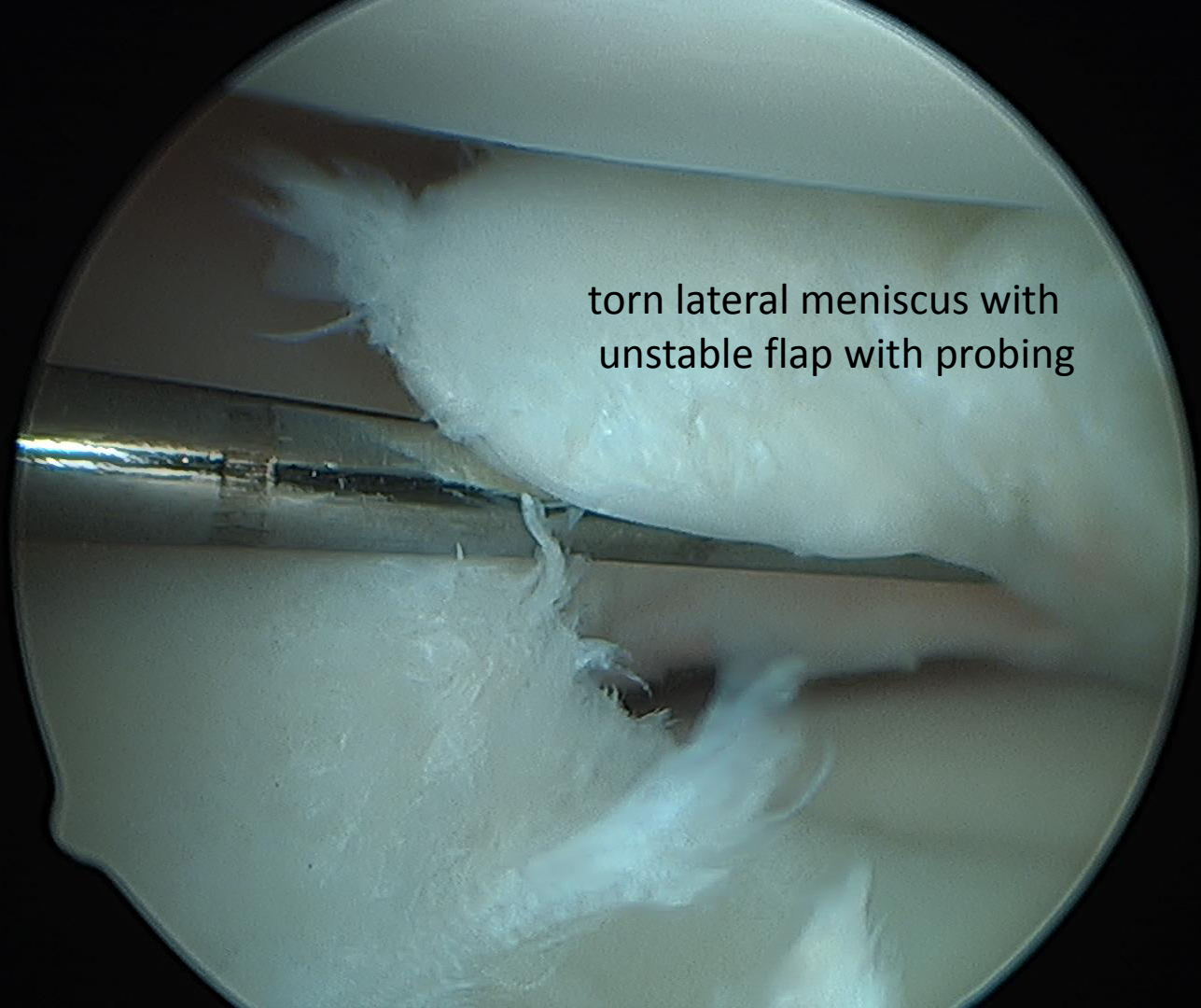
torn lateral meniscus



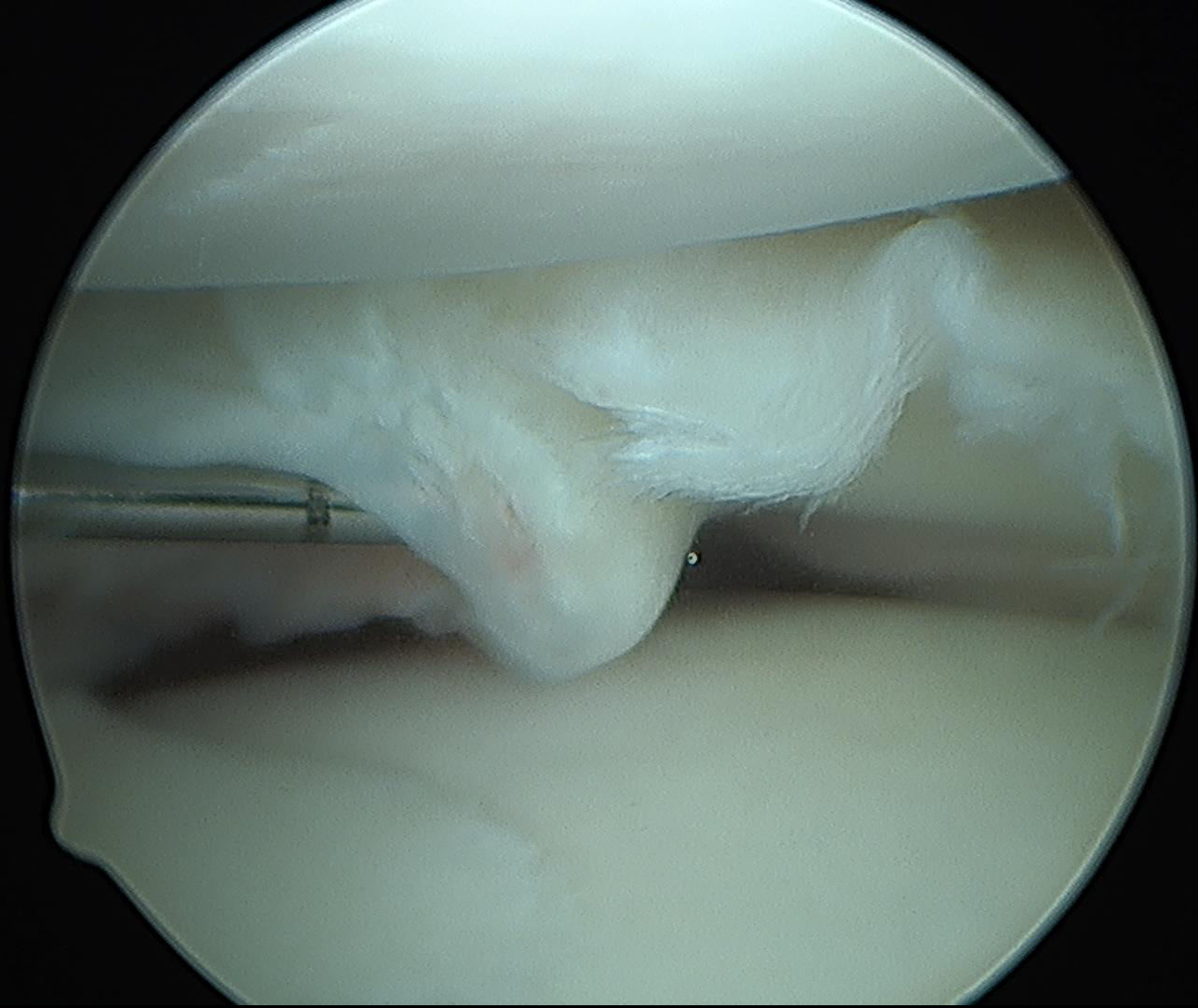
torn lateral meniscus →

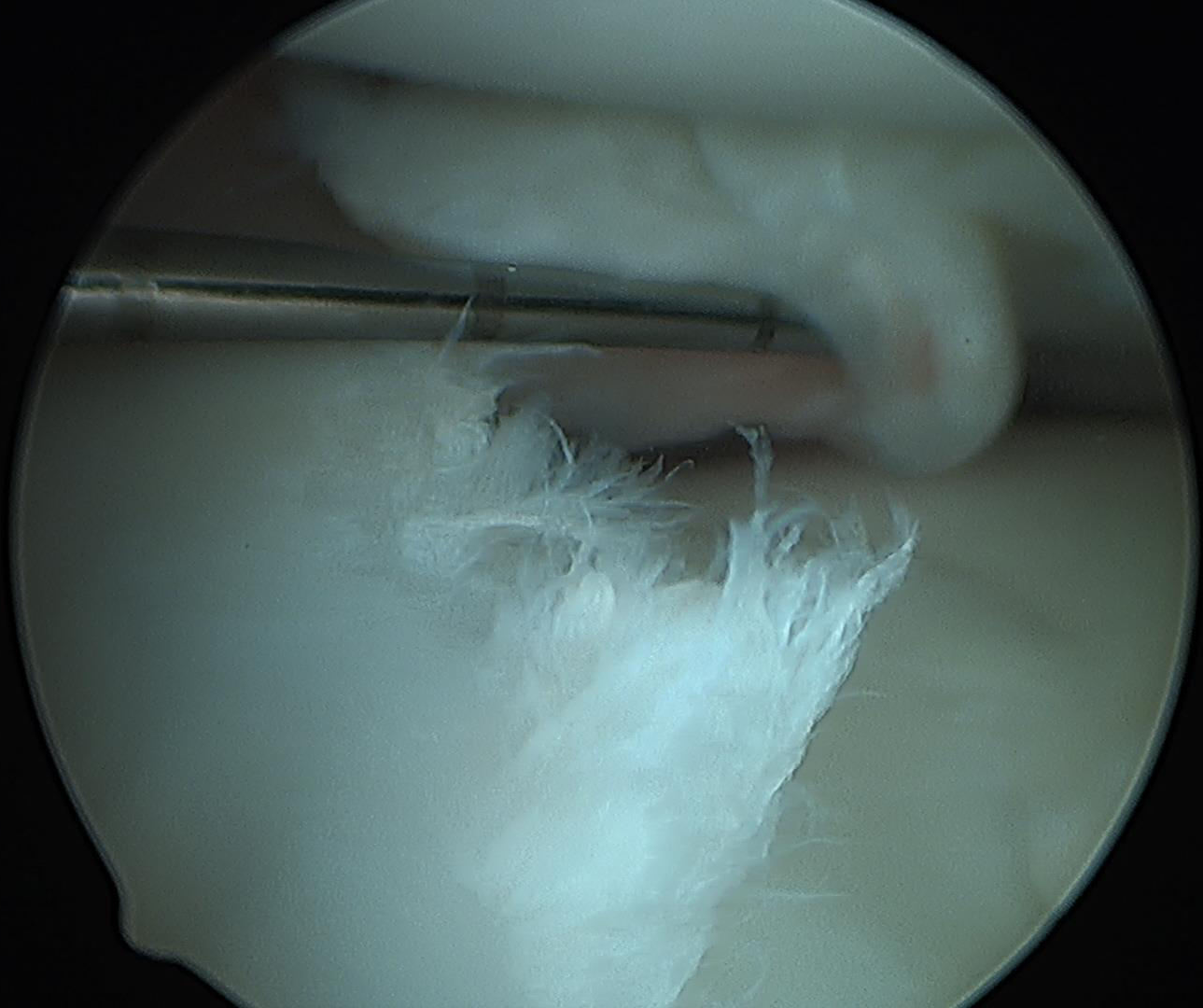




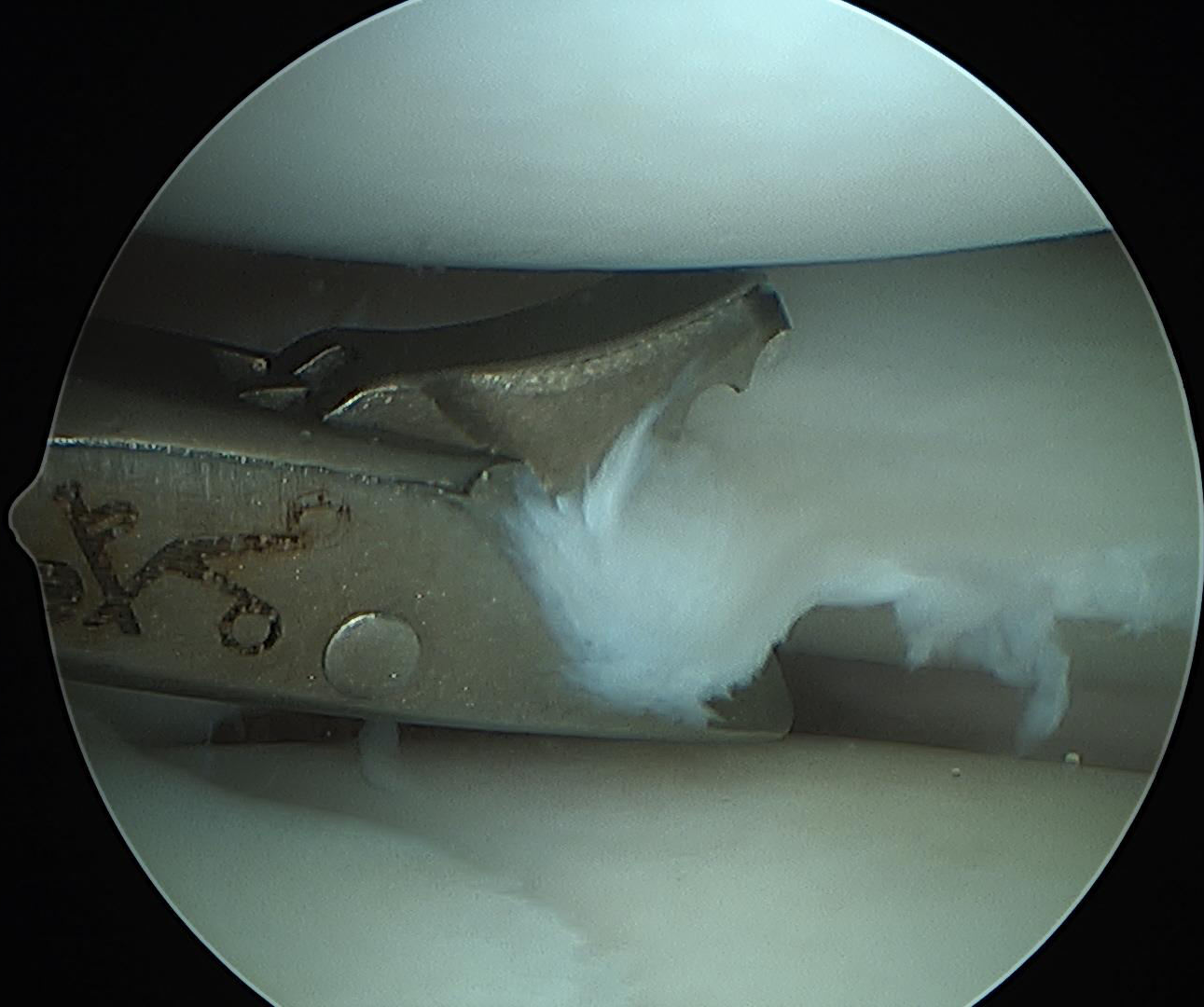


torn lateral meniscus with  
unstable flap with probing






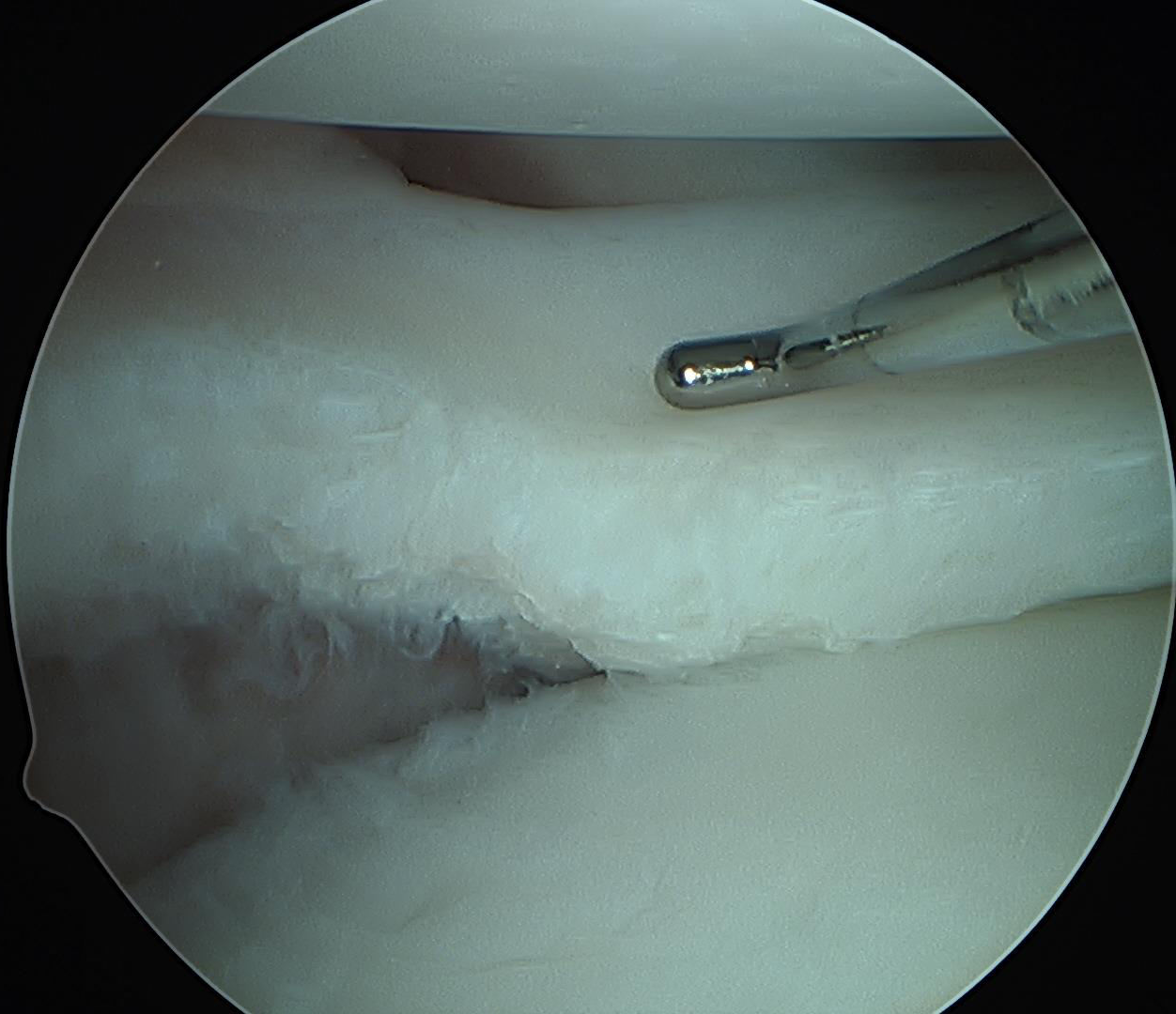




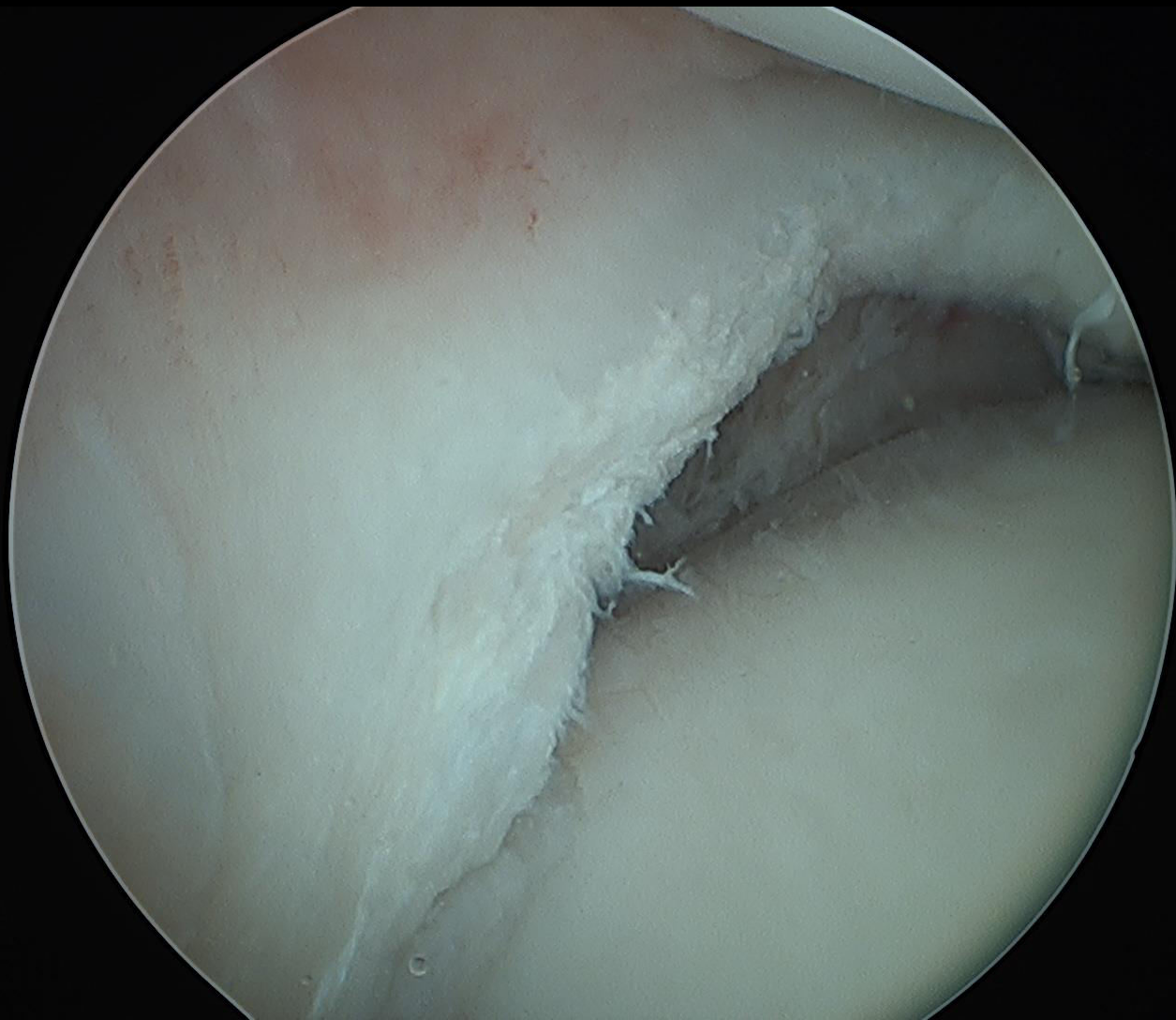
Partial lateral meniscectomy with meniscal biter



Partial lateral meniscectomy completed



Partial lateral meniscectomy completed



Partial lateral meniscectomy completed